

Slice Plastination and Shrinkage

MIRCEA-CONSTANTIN SORA¹, MAXIMILLIAN BINDER¹, PETRU MATUSZ², HORIA PLES^{3*}, IOAN SAS⁴

¹Medical University of Vienna, Plastination Laboratory, Center for Anatomy and Cell Biology, Plastination and Topographic Anatomy, Waehringerstr. 13/ 3, A-1090 Wien, Austria

²"Victor Babes" University of Medicine and Pharmacy Timisoara, Department of Anatomy, 2 Eftimie Murgu Sq., 300041, Timisoara, Romania

³"Victor Babes" University of Medicine and Pharmacy Timisoara, Department of Neurosurgery, 2 Eftimie Murgu Sq., 300041, Timisoara, Romania

⁴"Victor Babes" University of Medicine and Pharmacy Timisoara, Department of Obstetrics and Gynecology, 2 Eftimie Murgu Sq., 300041, Timisoara, Romania

Plastination suits very good for 3D reconstruction and morphometric measurements. Digital representation of anatomical features has provided a useful source of data for computer-based instructional development. The validation of 3D reconstructions and measurements needs a thoroughly knowledge about shrinkage. The aim of this paper is to determine the average slice shrinkage rate occurring during sheet plastination (E12 and P40). Fresh human brain slices for P40, pelvis slices for the standard E12 technique and a shoulder tissue block for the E12 thin slice technique were used for this study. In order to determine the shrinkage rate, the slice areas were measured before and after plastination for all samples. For the E12 thin slice technique, the shoulder tissue block was measured before and after plastination and a volumetric shrinkage rate was determined. The shrinkage rate was for P 40 technique 5.74%, for standard E12 technique 6.54% and for the E12 thin slices technique 6.23%. Therefore, plastinated slices showed a decreased shrinkage rate and fit best for research purposes. All shrinkage rates were under 10%, so we believe that every shrinkage below this value is appropriate and actually is fitted for a correct plastination procedure.

Keywords: plastination, polymer E12, polymer P40, shrinkage

As we all know, the process of plastination has, since its inception, taken giant strides and have been applied in a variety of fields. It has been used in the field of teaching to create examples for display purposes and, of course, plastination has been used as a tool in research [1-7]. It became quite clear that the process of plastination has the potential to be used in a numerous and especially various fields of interest. The most powerful plastination tool to be applied in research is the sheet plastination. The use of the sheet plastination method provides more accurate and precise data than those obtained with the use of dissection. Slice plastination performs no modifications or deformations of anatomic tissue, thereby making this technique a valuable tool in the evaluation of topographic relations. For keen anatomists, one of the main challenges is to obtain accurate 3D reconstruction of specific complex anatomical regions [8-10]. Surgeons require these to obtain both precise anatomical knowledge and surgical orientation [11-14]. Surgeons and radiologists can view these 2D images and usually create a mental model of 3D structures in the study. However, many anatomical structures have a complex morphology that passes in and out of the cross sections [15, 16]. Plastination has been proposed as a suitable method to provide geometrical data for 3D reconstruction of hard and soft tissue. Transparent serially-sectioned plastinated slices reveal visual clarity of gross structures under submacroscopic levels [16]. One of the most common critics when dealing with plastination in research is shrinkage. The main fields of using slices plastination in research are morphometric measurements or 3D reconstructions. In order to validate the obtained data, it is needed to know the shrinkage rate of the specimens. As it is known, shrinkage occurs during plastination, but the

question to be answered is: How high should be an acceptable shrinkage? The purpose of this article was to evaluate the shrinkage during sheet plastination of P40 brain slices, E12 body slices and E12 thin slice plastination.

Experimental part

P40 brain slices

A human brain was obtained post-mortem. The brain was maintained for one month in 5% formalin. Before being serially sectioned, the brain was washed in running tap water for one day. By using a meat slicer, the brain was sliced into 16 sagittal slices with a thickness of 4 mm. The obtained slices were placed into two grid baskets and into distilled water at +5 °C overnight [17]. The slices were placed then into an acetone bath at -25 °C. After two days the grid baskets containing the slices were moved into another acetone bath, also at -25°C. Dehydration was completed after one week and the slices were scanned. The slices were placed with the grid basket into the immersion bath of P40 at -25 C for one day. Following this procedure, the brain slices were taken from the immersion bath (-25 °C) and placed in cold P40 at -25 °C in the vacuum chamber. The vacuum chamber was then placed in a freezer at -25°C. Impregnation was undertaken for 12 h and completed under reduced pressure (2mm Hg) [18]. All slices were casted in flat chambers and the chambers subject to UV irradiation for 3 h. The finished plastinated slices were once again scanned in order to determine the shrinkage rate between the fresh and plastinated slices.

Standard E12 body slices (3mm)

One female pelvis used for this study was removed from a fresh unfixed cadaver and then frozen at -80 °C for one week. In the next step slices with an average thickness of

* email: horia.ples@neuromed.ro; Tel.: 0744554540

3 mm were cut by using a band saw. Numbering markers were placed on the cranial side. The slices were stored at -25 °C overnight. The slices were plastinated according to the standard E12 slice plastination method [1, 9]. Freeze substitution is the standard dehydration procedure for plastination, the shrinkage is minimized when cooled acetone is used. The slices were submerged in cold (-25 °C) pure acetone for dehydration. Degreasing was performed by using methylene chloride. Impregnation was performed using the following epoxy Biodur (Heidelberg, Germany) mixture: E12 (resin)/ E1 (hardener) [9]. The original size of the frozen slices and their size after dehydration were scanned with an Epson GT-10000+ Color Image Scanner.

Thin slice E12 plastination (1mm)

One male shoulder was frozen at -80 °C for one week. Afterwards, it was plastinated according to the standard ultra-thin E12 slice plastination method [4, 19]. The tissue block was submerged in cold (-25 °C) pure acetone for dehydration. Degreasing was performed by using methylene chloride. Impregnation was performed using the following epoxy Biodur (Heidelberg, Germany) mixture: E12 (resin)/ E6 (hardener)/ E600 (accelerator) [19]. When impregnation was completed, the tissue block was removed from the vacuum chamber. A mould of styrofoam was constructed and lined with polyethylene foil. The tissue block was inserted into the mould. The mould containing the impregnated specimen and resin-mix was kept at 65 °C in oven, for four days to assure the hardening of the resin-mix. The tissue/resin block was cooled at room temperature and the mould was removed. A contact point diamond blade saw, Exact 310 CP (Exact Apparatebau GmbH, Norderstedt, Germany) was used for cutting the block in 1 mm slices. Prior to plastination, the length, width and depth of the frozen tissue block was measured after placing markers into the tissue block. Following plastination, the same parameters were measured at the same spots as before plastination.

Results and discussions

P40 brain slices

In order to calculate shrinkage, the surface area of each brain slice was measured before and after plastination. Each slice was scanned into the computer. The finished plastinated slices were once again scanned to determine the shrinkage rate between the fresh and plastinated slices. The surface area of each slice was calculated by using the UTHSCSA Image Tool software for Windows, version 3.0 (University of Texas Health Science Centre at San Antonio, San Antonio, TX). By comparing the area of the fresh and of the plastinated slices a two dimensional shrinkage was calculated. P40 slices had a shrinkage rate of 5.74%. (table 1).

Standard E12 body slices (3mm)

Table 1
MEASUREMENTS OF BRAIN SLICES BEFORE AND AFTER P40 PLASTINATION (n = 10)

Parameters analyzed	Fresh cut	After P40 plastination
Average slice area (cm ²)	1200.75	1132.81
Standard deviation	1.74	1.36
Average shrinkage (%)	-	5.74
Standard deviation	-	1.31
Shrinkage t-test	-	0.67
Shrinkage significance	-	not significant

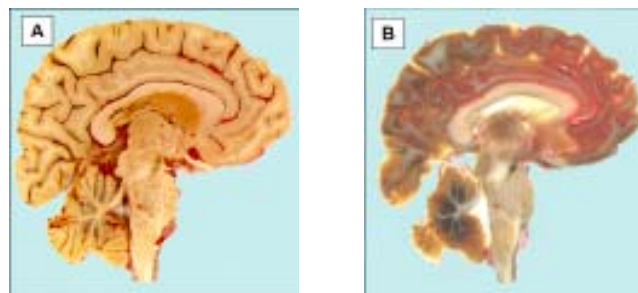


Fig.1. Mediosagittal section of the brain: A-fresh cut brain slice; B- P40 plastinated slice

The surface area of each slice was measured before and after plastination. Each slice was scanned into the computer. The average shrinkage after standard E12 plastination was 6.54 %. This value is reasonable, with regard to the plastination conditions. Once again, we observed that some slices shrank more than others. A possible explanation could be the fact that these slices contain more lipid tissue than others. In order to investigate the shrinkage of different tissue types, we measured on the slices the muscle areas and connective tissue area before and after plastination. The connective tissue had a shrinkage rate of 7.22% and the muscles had shrinkage of 6.82%.

Table 2.
MEASUREMENTS OF BODY SLICES BEFORE AND AFTER STANDARD E12 PLASTINATION (n = 14)

Parameters analyzed	Fresh cut	After E12 plastination
Average slice area (cm ²)	8951.67	8366.65
Standard deviation	1.28	1.41
Average shrinkage (%)	-	6.54
Standard deviation	-	1.11
Shrinkage t-test	-	0.99
Shrinkage significance	-	not significant

Thin slice plastination (1mm)

To determine shrinkage resulting from the plastination process, the tissue block from the body was first measured immediately after removal and subsequently following plastination. Prior to plastination, the length of the shoulder block from the superior pole to the inferior pole was measured and the depth and width were determined in the middle of the anterior surface. Needles were used as markers to define the measurements points. By comparing the data of the fresh tissue block and the measurement data of the plastinated block, the amount of shrinkage of the specimen was calculated to be 6.23%.

In plastination studies, shrinkage is a main topic. Independent of the technique used (S10, E12 or P40), the process will generate shrinkage. Numerous investigators studied the shrinkage rate of specimens during the S10 technique [20-25], but the shrinkage in E12 and P40 technique has been studied briefly [26-28]. The question is: Why is shrinkage so relevant? Firstly, because a considerable shrinkage will decrease the value of the specimens and distort the initial shape. Secondly, because shrinkage determines considerable deviations from the original specimen size. This second reason is very important when dealing with morphometric measurements and 3D reconstructions. As we all know, slice plastination (E12, P40) has the highest impact in applying plastination as a research tool. Only by considering the shrinkage rate in our calculations, the morphometric measurements and 3D reconstructions could be valid.

Since the beginning of plastination, the E12 technique was, and still is, the elected method for producing

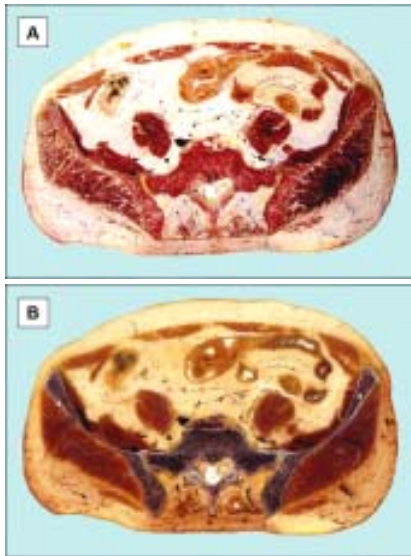


Fig.2. Transversal section of the trunk at the level of lower abdomen: A-Fresh cut abdominal slice; B-E12 plastinated slice.

transparent body slices. Transparent body or organ slices are used for teaching and research purposes, because they allow studying the topography of all body structures in a non-collapsed and non-dislocated state. In addition, the specimens are useful in advanced training programs in sectional topography (resident training in CT and NMR). Most of the research studies deal with the topography of anatomical structures. However, if distances between structures or calibers of vessels are to be measured on plastinated slices, correct results can only be obtained when the shrinkage rate is considered. Two factors contribute to the amount of shrinkage: the shrinkage of the epoxy polymer itself and the shrinkage of the tissue slices during the plastination process. The observed shrinkage of the E12 resin was found to be less than 0.2%. These results are comparable to data we obtained from the CIBA Company (Ciba Spezialtätenchemie GmbH, Vienna, Austria). The shrinkage values determined in the present study represent only the two-dimensional shrinkage. The shrinkage rate of 6.54% represents actually the shrinkage of the tissue slice during dehydration, degreasing and impregnation. As the slice consists of different tissue types we observe that the connective tissue shrink most, having a shrinkage rate of 7.42% followed by the muscular tissue with a shrinkage rate of 6.92%. Bony tissue does not shrink and contribute to the shape conservation of the slice.

In the last decade, plastinators started to use more frequently P40 as an alternative for E12. There is mainly one reason for this, i.e. the epoxy resin turns yellow in time and the colour of the slices get dark, but polyester remains clear, without changing the colour. A disadvantage of polyester resin is the lower breaking index, so the transparency of the connective tissue will be diminished. We know that unsaturated polyester resins can usually shrink 5 to 8% during the transition from the liquid to the solid state [29-30], but this is a 3D shrinkage. Our measurements determined a shrinkage value of 5.74%, which is bidimensional and seems to be acceptable in this context. P40 plastination is, in our opinion, the best method to preserve brain slices. Furthermore, we consider that the P40 technique is much better than the S10 standard technique for plastination of brain slices, where shrinkage can reach up to 10% [31].

Digital representation of anatomical features has provided a useful source of data for computer-based instructional development. In fact, the development of multimedia tools for anatomical learning has received much attention, spawning the new field of anatomical

informatics [32]. However, an initial cadaveric data source is necessary to facilitate creation of multimedia resources. Plastination serves as one human tissue preservation technique that involves the replacement of water and lipids with curable polymers that are subsequently hardened [33]. The E12 thin slice technique has proved particularly useful for 3D reconstruction of anatomical structures and should serve well as a data source for multimedia [16]. In order to generate 3D structures, we need firstly to build up a plastinated tissue block and then to cut it in thin (1mm) slices. In this case, we can calculate only a 3D volumetric shrinkage of our tissue block, but not shrinkage of different tissue types. The calculated shrinkage (length/ width/ depth) in our study was 6.23% and there are not literature data to compare to. We know that epoxy resin practically do not shrink, so we could regard this shrinkage as the shrinkage of the tissue block during plastination. When dealing with 3D reconstruction, the main parameters are length and width. These parameters will be always being asked at the beginning of each reconstruction. The third dimension, the thickness of the slice, is always the thickness of the original slices cut from the fresh tissue block, which is known from the beginning. In regard of this, the main shrinkage that has to be known is the bidimensional (length/ width) one.

But how high could be an acceptable shrinkage rate? Theoretically, if we calculate it for every slices and tissue type, we can accept every shrinkage rate that occurs. On the other hand, for high shrinkage rates, the original specimen size is lost. Combined with the tissue lost during specimen sawing, all calculations or 3D reconstructions could deviate and be distort. That is the reason why this study tries to define an acceptable shrinkage rate for E12 and P40 plastination. As von Hagens [17] stated that up to 10% is unavoidable during plastination, we believe that every shrinkage rate, for the E12 and P40 method, which is lower than this value is very good and actually is a feedback for a correct plastination procedure.

References

1. SORA MC, MATUSZ P. General considerations regarding the thin slice plastination technique. *Clin Anat.*, 2010, 23(6):734-736.
2. SORA MC, JILAVU R, MATUSZ P. Computer aided three-dimensional reconstruction and modeling of the pelvis, by using plastinated cross sections, as a powerful tool for morphological investigations. *Surg Radiol Anat.*, 2012, 34(8):731-736.
3. BEDREAG, O., BUT, AR., HOINOIU, B., MICLAUS, GD., URSONIU, S., MATUSZ, P., DOROS, CI. Using Pig Tracheobronchial Corrosion Casts in Training of the Medical Students and Residents. *Mat. Plast.*, 2014, 51(4):444-447.
4. WENGERT, GJ., BARTL, R., SCHUELLER-WEIDEKAMM, C., GABRIEL, A., MATUSZ, P., SORA, MC., *Mat. Plast.*, 51, no. 4, 2014, p. 452
5. IVAN, C., NICA, CC., DOBRESCU, A., BELIC, O., MATUSZ, P., OLARIU, S. *Mat. Plast.*, 52, no. 1, 2015, p. 48
6. SORA, MC., FEIL, P., BINDER, M., MATUSZ, P., PLES, H., *Mat. Plast.*, 52, no. 1, 2015, p. 75
7. IOANOVICIU, SD., IVAN, C., MATUSZ, P., OLARIU, S., LIGHEZAN, D. *Mat. Plast.*, 52, no. 1, 2015, p. 113
8. LOUKAS, M., ABEL, N., TUBBS, RS., MATUSZ, P., ZURADA, A., COHEN-GADOL, AA. Neural interconnections between the nerves of the upper limb and surgical implications. *J Neurosurg.*, 2011, 114(1):225-235.
9. MATUSZ, P., MICLAUS, GD., PLES, H., TUBBS, RS., LOUKAS, M. Absence of the celiac trunk: case report using MDCT angiography. *Surg Radiol Anat.*, 2012, 34(10):959-963.
10. MICLAUS, GD., MATUSZ, P. Bilateral quadruple renal arteries. *Clin Anat.*, 2012, 25(8):973-976.

11. HULSBURG, P., GARZA-JORDAN JDE, L., JORDAN, R., MATUSZ, P., TUBBS, RS., LOUKAS, M. Hepatic aneurysm: a review. *Am Surg.*, 2011, 77(5):586-591.
12. PETRIE, A., TUBBS, RS., MATUSZ, P., SHAFFER, K., LOUKAS M. Obturator hernia: anatomy, embryology, diagnosis, and treatment. *Clin Anat.*, 2011, 24(5):562-569.
13. OSIRO, S., TIWARI, KJ., MATUSZ, P., GIELECKI, J., TUBBS, RS., LOUKAS, M. Grisel's syndrome: a comprehensive review with focus on pathogenesis, natural history, and current treatment options. *Childs Nerv Syst.*, 2012, 28(6):821-825.
14. DEAN, C., ETIENNE, D., HINDSON, D., MATUSZ, P., TUBBS, RS., LOUKAS, M. Pectus escavatum (funnel chest): a historical and current prospective. *Surg Radiol Anat.*, 2012, 34(7):573-579.
15. QIU, MG., ZHANG, SX., LIU, ZJ., TAN, LW., WANG, YS., DENG, JH., TANG, ZS. Plastination and computerized 3D reconstruction of the temporal bone. *Clin Anat.*, 2003, 16(4):300-303.
16. SORA, MC., GENSER-STROBL, B., RADU, J., LOZANOFF, S. Three-dimensional reconstruction of the ankle by means of ultrathin slice plastination. *Clin Anat.*, 2007, 20(2):196-200.
17. von HAGENS, G. Heidelberg Plastination Folder: Collection of all technical leaflets for plastination, 2nd Ed. ed. Anatomisches Institut 1, Universitat Heidelberg, Heidelberg, Germany, 1985.
18. HENRY, RW., LATORRE, R. P40 technique for brain slices. *J Int Soc Plastination*, 2007, 22:59-68.
19. SORA, MC., COOK, P. Epoxy plastination of biological tissue: E12 technique. *J Int Soc Plastination*, 2007, 22:31-39.
20. SCHWAB, K., von HAGENS, G. Freeze substitution of macroscopic specimens for plastination. *Acta Anat.*, 1981, 111: 139-140.
21. RIPANI, M., BASSI, A., PERRACCHIO, L., PEREZ, M., BOCICIA, ML., MARANOZZI, G. Monitoring and enhancement of fixation, dehydration, forced impregnation and cure in the standard S-10 technique. *J Int Soc Plastination*, 1994, 8:3-5.
22. BROWN, MA., REED, RB., HENRY, RW. Effects of dehydration mediums and temperature on total dehydration time and tissue shrinkage. *J Int Soc Plastination*, 2002, 17:28-33.
23. REED, RB., HENRY, RW. Shrinkage assessment with classic plastination dehydrants. *J Int Soc Plastination*, 2002, 17:9-11.
24. PEREIRA-SAMPAIO, MA., MARQUES-SAMPAIO, BPS., SAMPAIO, FJB., HENRY, RW. Shrinkage of renal tissue after impregnation via the cold biotur plastination technique. *Anat Rec Adv Integr Anat Evol Biol.*, 2011, 294(8):1418-1422.
25. SHANTHI, P., SINGH, RR., GIBIKOTE, S., RABI, S. Comparison of CT numbers of organs before and after plastination using standard S-10 technique. *Clin Anat.*, Epub ahead of print 2015 Feb 23, doi: 10.1002/ca.22514
26. SORA, MC., STROBL, B., STAYKOV, D., TRAXLER, H. Optic nerve compression analyzed by using plastination. *Surg Radiol Anat.*, 2002, 24(3-4):205-208.
27. SEBE P, FRITSCH H, OSWALD J, SCHWENTNER C, LUNACEK A, BARTSCH G, RADMAYR C. Fetal development of the female external urinary sphincter complex: An anatomical and histological study. *J Urol.*, 2005, 173(5):1738-1742.
28. SORA, MC., GENSER-STROBL, B. The sectional anatomy of the carpal tunnel and its related neurovascular structures studied by using plastination. *Eur J Neurol.*, 2005, 12(5):380-384.
29. ARPE, H-J., SCHULZ, G., ELVERS, B. Ed., Ullmann's Encyclopedia of Industrial Chemistry. 5th Ed., Weinheim, VCH Publishers, 1992, Vol. 21, pp 217-225.
30. KIRK-OTHMER. Encyclopedia of chemical technology. 4th Ed., New York, Wiley, 1996, vol 19, pp 654-677.
31. SURIYAPRAPADILOK, L., WITHYACHUMNARNKUL, B: Plastination of stained section of the human brain: Comparison between different staining methods. *J Int Soc Plastination*, 1997,12(1):27-32.
32. TRELEASE, RB. Anatomical informatics: Millennial perspectives on a newer frontier. *Anat Rec (New Anat).*, 2002, 269(5):224-235.
33. von HAGENS, G., TIEDMANN, G., KRIZ, W. The current potential of plastination. *Anat Embryol.*, 1987, 175(4):411-421

Manuscript received: 22.09.2014