

Evaluation of Marginal Periodontium Adjacent to the Reconstruction Materials in the Dental Prosthetics

Study Morphopathological and Immunohistochemical

ATENA GALUSCAN¹, MARIOARA CORNIANU, DANIELA JUMANCA^{1*}, ALEXANDRA FAUR, ANGELA PODARIU¹, LAVINIA ARDELEAN³, LAURA CRISTINA RUSU³

¹ University of Medicine and Pharmacy "Victor Babes" Timisoara, Department of Preventive, Community Dentistry and Oral Health, 2 Eftimie Murgu Sq., 300041, Timisoara, Romania

² University of Medicine and Pharmacy "Victor Babes" Timisoara, Department of Morphopathology, 2 Eftimie Murgu Sq., 300041, Timisoara, Romania

³ University of Medicine and Pharmacy "Victor Babes" Timisoara, Dental Materials Technology, 2 Eftimie Murgu Sq., 300041, Timisoara, Romania

Dental restoration materials act as a local irritating factor superimposed to the bacterial factors, and the inflammatory and immune response of the marginal periodontal tissue leads to replacement of the functional structures with granulation tissue that continues to grow in size, while the subgingival dental plaque is heading to the lateral and apical areas. We evaluated morphologically and immuno-histochemically the marginal periodontium adjacent to the fixed metallic-alloyed prostheses (Cr-Ni), composite resins (Cromasit) and ceramic (Vita-Ceram), but also some of the patients with periodontitis which were not associated with prosthetic devices. By the morphological analysis of the periodontal components we reported structural microscopic alterations closely correlated with macroscopic changes observed during clinical examination. We observed a direct relationship between the proportion of inflammatory infiltrate / collagen fibers according to the type of material adjacent to the periodontal tissue. By immunohistochemical evaluation we observed that regeneration and re-epithelizing process appear to be delayed by: persistent inflammatory infiltrate in the epithelial spurs, the presence of fibrinous exudate, fibro-purulent and blood cells on the surface of mucosa. Immunohistochemical investigation in marginal periodontitis watched the evaluation of the immunoreactivity in the periodontal morphological substrates toward the proliferation markers of the gingival epithelium (Ki-67), as well as the mesenchymal reactions specific to the healing process in periodontal lesions (CD -31). The morpho-pathological changes of the periodontal tissue are more profound in the presence of the dental prostheses than in the patients without any such devices and also the regenerative epithelial capacity of the damaged periodontium is more reduced in patients with prostheses than in those without.

Keywords: dental materials, parodontium, imunohistochemistry, morphopathology

Dental Medicine allows the reconstruction of the damaged dental tissues with complex prosthetic devices, made of various specific materials. How these materials rehabilitate and influence the adjacent periodontal tissue depend on the used materials, their mode of processing and also of the specific properties of periodontium. Structural and functional features of the marginal periodontium are influenced by: the rate of tono-filaments/cytoplasm (which is sub unitary); the proportion of periodontal desmosomes is four times lower than in other epithelia, thus possibilities of more rapid cell- detachment from the epithelium toward the surface of mucosa; epithelial cells have well-developed organelles involved in protein and glycols synthesis (rough endoplasmic reticulum, complex Colgi); cells attachment to the tooth surface is similar to the interface epithelium-conjunctive tissue; cells secrete a basal lamina or cuticular substance on the tooth surface; the cells attach to the cuticle through hemi-desmosomes; the junctional epithelium turnover is rapid, with a high rate of cell replacement, between 4-6 days; cellular divisions are 6 times faster than in other areas of the oral epithelium; basal cells migrate to the epithelium surface, then peel; in disturbances of cellular migration

dynamics, the gingival ditch (sulcus) becomes deep (inflammation, irritation caused by instruments, masticatory impact, plaque or calculus developing and immune response to bacterial antigens) [1-5].

The composition of the gingival crevicular fluid is 95% PMN (neutrophiles), 2-3% monocytes, 1-2% lymphocytes (B - 70% and T - 30%), immunoglobulin, transferrin, fibrinogen, cytokines, IL-8. In the crevicular fluid there is a mixture of serum-derived substances including electrolytes, organic molecules, proteins, antibodies, enzymes of bacterial origin and from host-organism. In periodontitis, they are described as components of bone cells resulted from the lyses of the alveolar bone, from tisular fragments and growth factors from the tissue of the host-organism. These ones represent precise morphological indicators of periodontitis [6,9].

Dental restoration materials act as a local irritating factor added to the bacterial factors, and inflammatory and immune response of marginal periodontal tissue structures leads to replacement of the functional structures with granulation tissue that continues to grow in size, while the subgingival dental plaque is heading to the lateral and apical side [7,8].

* email: djumanca@clicknet.ro, tel: 0744926202

Experimental part

Materials and methods

Our study material was consisted in *gingival mucosa fragments* adjacent to the fixed prostheses and fragments of gingival mucosa collected from patients with periodontitis but no fixed prostheses. The patients were evaluated according to their type of prostheses (metal, metal-composite metal-ceramic) and also to their periodontal damage: gingivitis, periodontitis. All these cases were investigated clinically and radiological according to the encountered situations. For this purpose, we performed their detailed history and also we carried out the dental records of patients; by examining the panoramic and retroalveolar radiographs, we assessed the degree of evolution of the disease and the level of periodontal tissue destruction. The selected patients had fixed prostheses older than 5 years with obvious clinical signs of impaired periodontal (gum hypertrophy, bleeding on probe palpation, periodontal pockets and gingival retractions). We examined 36 patients with periodontal disease associated with prosthetic devices, and also from whom 42 gingival biopsies were collected, and then a group of 31 patients with marginal periodontitis, but not associated with prosthetic devices. In this group of patients, the age ranged from 27 to 57 years, with an average of 47.6 years. Out of these, 60% were females and 40% males.

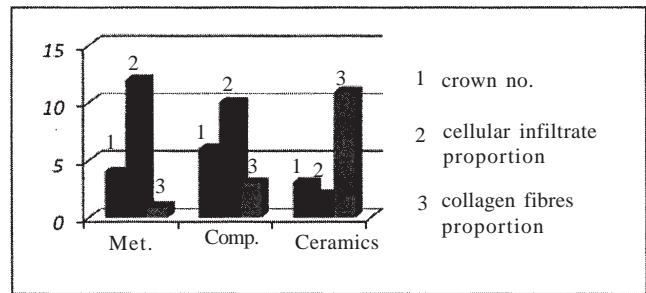
Fixed prostheses were made of classic materials used in dentistry, older than 5 years. The crown metal is a classic chromium-nickel alloy, and the composite in the semi-physiognomic prosthesis is type Cromasit. Metal-ceramic prostheses are totally esthetic and are made of VITA-Ceram on metallic frame. Criteria for selection of cases and periodontitis classifications were based specifically on the clinical aspects of lesions (color, bleeding, probing depth of periodontal probe) and X-ray (which showed the level of bone resorption).

Tissue fragments were collected by surgical excision during periodontal interventions.

Fragments of mucosa were evaluated morphopathologically and immunohistochemically. Biopsies were processed after the routine histological manner with fixation in formaldehyde 10%, inclusion in paraffin and sectioning at 3-4 μ .

Morpho-pathological examination

Biopsies were fixed in formalin 10%, then included in paraffin and after that processed by usual known methods,



Graphic 1. Cellular infiltrate and collagen fibers, evident on the microscopic preparations

the sections being stained with hemotoxylin-eosin (HE), Tricrom Gömöri.

It is known that periodontal disease is accompanied by the presence of a cellular infiltration and the destruction of collagen fibers in its lamina. In order to establish the degree of periodontal damage and some prognostic criteria we watched the proportion of the collagen fibers/inflammatory cellular infiltrates in periodontitis associated with fixed prostheses.

In most cases, ulceration areas were found in the gingival bag and as well as epithelial regeneration areas. Areas of ulceration continue with a rich lymphocytic infiltrate, plasmocytes, histocytes, macrophages, granulocytic, fibrocytic and fibroblastic, and sometimes and fibrinous exudates.

Towards the periphery of the cellular infiltrate, fibrocytes, fibroblasts and capillaries of neoformation become more numerous, pointing out the presence of collagen fibers, which later rearrange in fibrous bundles. The proportion of two components - cellular infiltrate and collagen fibers, evident on the microscopic preparations, is presented in graphic 1.

The cellular infiltrate is poorly represented in the periodontium around the ceramic crowns (fig. 1a); it represents less than 3/4 of the preparation surface in periodontitis adjacent to the composite crowns (fig. 1b), becoming predominant in case of the metal crowns (fig. 1c).

Immunohistochemical investigation in marginal periodontitis was intended to evaluate the immunoreactivity of the morphological substrates compared to the proliferation markers of the gingival epithelium (Ki-67), and also the mesenchymal reactions specific to healing process in periodontal lesions CD(-31).

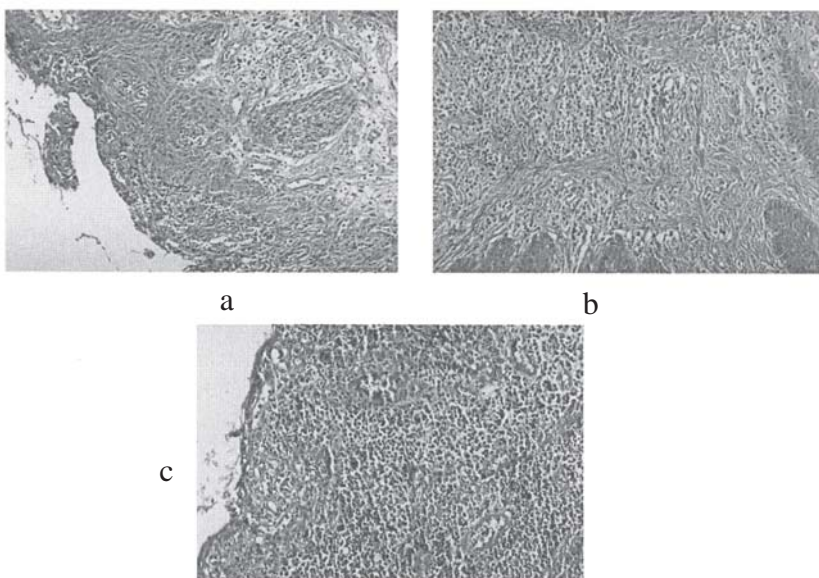


Fig. 1. (a) Periodontal tissue adjacent to the ceramic crowns, cellular infiltrate slightly represented. Tricrom Gömöri x 200. (b) Periodontal tissue adjacent to composite crowns, the presence of moderate cellular infiltrate. Tricrom Gömöri x 200. (c) Intense cellular infiltrate associated with periodontal tissue adjacent to a metal crown. HE x 200

Clinical and pathological factors	Number of cases	Ki-67 labeling index Indice de marcare Ki-67 IM Ki-67% (limits)
masculine	17	2.4%(0,2%-3,5%)
feminine	14	2.5%(0,4%-3,6%)
<50 years of age	26	2.9%(0,2%-3,6%)
>50 years of age	16	2.3%(0,1%-3,5%)
Associated prosthetics	42	
<i>types of crown:</i>		
metallic	9	2.5% (0,3%-3,5%)
composite	11	2.3% (0,2%-3,6%)
ceramic	10	2.4% (0,3%-3,6%)

Table 1
Ki-67 LABELING INDEX (IM Ki-67) AND
THE STUDIED CLINICAL AND
MORPHOLOGICAL PARAMETERS

Ki-67: We evaluated the proliferative capacity of gingival mucosa epithelium by applying immunohistochemical reaction to identify Ki-67 antigen using LSAB technique. For the immuno-histochemical prove of antigen Ki-67, we used Ki-67 monoclonal antibody anti Ki-67 Clona MIB-1, which recognizes a nuclear antigen of cellular proliferation (a doublet of proteins with molecular weight of 345 and 395 Kda) expressed in all the phases of cellular cycle, except G 0 phase. Tissue sections were pretreated by boiling for 60 min at 90° C in solution Retrieval, and then incubated 10 min with prediluted antibody MIB-1. The final product of reaction (brown colored) was obtained by visualization with DAB and anti-staining with hemotoxyline. For the negative control of the reaction, the primary antibody was replaced with a buffer solution, and for the positive control we included in the study a fragment of tonsil.

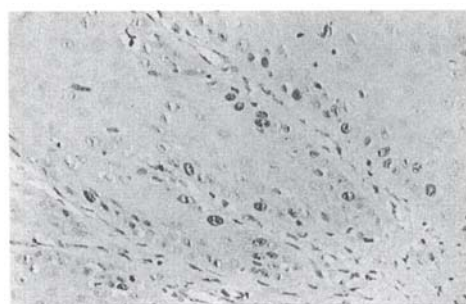
Ki-67 antigen has an exclusive nuclear localization, immunohistochemical labeling of the sections with MIB-1, identifying a pattern of staining confined to the nucleus. We considered as a positive response, any detectable nuclear staining (in dots or diffuse) regardless of the intensity of reaction, Ki-67 positive epithelial cells showing a brown nuclear staining, homogeneous or granular type. To quantify the immunoreaction of Ki-67, we determined the percentage of Ki-67 positive cells. The quantification of reaction which I performed through the assessment of marking index Ki-67 (IM Ki-67), expressed as a percentage result of the number of positive Ki-67 cells, compared to 500 cells (positive Ki-67 and negative Ki-67). We noted the

absence of immunoreaction Ki-67 on the section of negative control and immunoreaction Ki-67 on sections of tonsil (included in the study as a positive control sample), considering the staining germinative centers and lymphoid follicles as a positive immunoreaction. Although all the examined sections were positive, in different areas of the epithelium (belonging to the same section), we reported a heterogeneity of immunoreaction, both in terms of staining intensity and the nuclear marker.

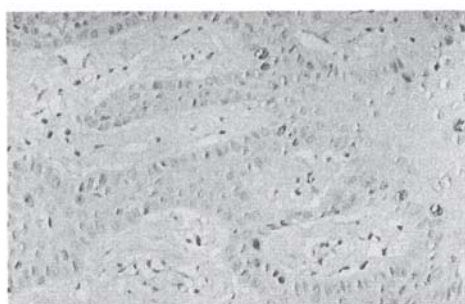
We correlated the expression and significance of the positive immunoreaction (IM Ki-67) with some of the clinical-morphological parameters, such as age and gender of the patients, the severity of inflammatory lesions of chorion mucosa, presence or absence of periodontal pockets (table 1).

No relationship was noticed between the patients gender and Ki-67 IM, the values obtained being very close (table 1). Patients under 50 had a lesion accompanied by a slightly more intense expression of immunoreaction Ki-67. On the gingival biopsies collected from patients with prosthetic devices associated to the periodontal disease, there were no differences regarding immunoreactivity Ki-67 at the level of the epithelium.

This inflammatory lesions in the chorion (its own lamina), also in the marginal gum zone (with sero-fibrinous exudate and rich inflammatory infiltrate limfo-plasmocitar and granulocytes) and extension inside the depth of the gingival fibromucosa were accompanied by an increase in proliferative activity, referring to the basal layers of epithelium (fig. 2a and fig. 2b) with an IM Ki-67 between 2.7 and 3.5%.



a



b

Fig.2 (a) Gingival mucosal epithelium with immunoreaction Ki-67 + +. Reactive nuclei with nuclear marks granular and nucleolar dots, involving the basal layers. LSABx400 (viz.DAB). (b) Immuno staining Ki-67 positive with reactive nuclei focally dispersed, into epithelial spurs with penetrating in depth of the fibromucosa. LSABx400 (viz.DAB)

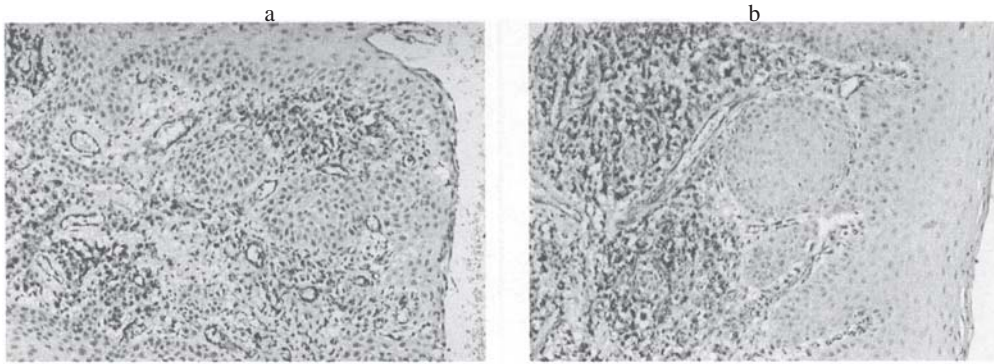


Fig. 3. (a) The morphological aspect of CD 31 + from the chorion of gingival mucosa collected near a ceramic prosthesis. Anti-CD 31, LSAB x 200 (viz.DAB). (b) The morphological aspect of the vessels in the chorion of the gingival mucosa. Anti-CD 31, LSABx200 (viz.DAB).

For immunohistochemical evaluation of morphological substrates CD 31 positive, we used the monoclonal antibody anti-CD 31, endothelial cells, clone JC/70A (DACO, Carpinteria, USA) by the LSAB technique. Tissue sections, representing fragments of mucosa were fixed in formalin and included in paraffin, previously treated by boiling them for 20 min at 95-99°C in a RETRIEVAL solution and then incubated with the primary antibody, the secondary antibody and streptavidina for 30 min. To visualize the reaction product, the sections were stained with DAB and contra-stained with hematoxylin. For the negative control of the reaction, the primary antibody was replaced with buffer solutions.

Immunohistochemical reaction which was carried out on all of the studied cases, showed the absence of staining in the control samples (-) and an immunoreactivity CD 31 constant positive but of a variable intensity in the endothelial cells of capillaries; they also expressed CD 31, the micro vessels from the area of the granulation tissue (with variable vascular density) as well as component cellular elements of the inflammatory infiltrate (lymphocytes, plasma cells, macrophages) from areas of ulceration and gingival fibro-mucosa.

In all the examined sections we noticed the presence of capillaries lined by endothelial cells CD 31(+), and the presence of endothelial cells isolated or clustered, here and there forming spots of endothelial cells CD 31(+), some of them outlining visible vascular lumens with or without content of intra-luminal red blood cells.

We investigated the morphological appearance of chorionic vessels CD 31 + in the gingival mucosa, as well as the architecture of the component microvessels in the granulation tissue at the bottom of ulceration. They were characterized by an irregular architecture, messy and uneven spatial distribution, with positive immuno-reaction CD 31 of variable intensity of endothelial cells.

We identified the presence of irregular size vessels and uneven lumens, some small, others elongated and then branched, anarchically dispersed among the inflammatory cells. (fig. 3a and fig 3b.).

Results and discussions

By this studied casuistry (survey), we proved a direct association between the severity of periodontal lesions and the proximity of some reconstruction crown materials frequently used in dentistry. We observed a direct relationship between the proportion of inflammatory infiltrate/collagen fibers depending on the material adjacent to the periodontal tissue. The relative density of fibroblasts and neofunction capillaries reached average values in the periodontium that surrounds the composite crowns, while around the ceramic crowns we noticed the largest relative density for both capillary and fibroblasts.

Most severe morphological changes were revealed along the lateral wall of the periodontal pocket: - proliferative

and degenerative changes of the epithelium - vacuolar degeneration of some cells, or progressive degeneration with epithelial necrosis and the appearance of erosions and extended ulceration of the bag side wall, then at the bottom of the bag having some nonspecific inflammatory granulation tissue rich in neofunction vessels and lymphocytomatic and granulocytic inflammatory infiltrates. Epithelial regeneration proved to be more intense and effective in the cases with limited ulceration and granulation tissue present in the surface chorion, sometimes accompanied by reconstruction of the epithelium associated with parakeratosis [10, 11,14] .

Data from literature claim that periodontitis occurs during an imbalance between the activated metalloproteins and their endogenous inhibitors, resulting in disintegration of the extracellular matrix [5,9,12]. Overall et al. established a correlation between the activity of tissular collagenase and the severity of inflammation. In human gum/gingiva, it has been noticed the association of collagenase with inflammatory cells. The same association was also observed in the studied material depending on the type of crowns associated to the marginal periodontitis. Cellular inflammatory infiltrate that represents the source of the above mentioned enzymes and of the acytokines is significantly higher in the periodontium associated to the metal crowns, the proportion cells/collagen fibers being 27/2, and in the periodontium adjacent to the ceramic crowns 3/22. The large proportion of inflammatory cells represents a criterion of the progression and severity rate of marginal periodontitis. Data provided by evaluating the relative density of fibroblasts and capillaries bring additional information on the evolution of periodontitis associated with the various types of materials used in prosthetic reconstruction of odontal lesions. Thus, adjacent to the ceramic crowns, the relative density of fibroblasts and capillaries has higher values than in the case of the metal crowns [15].

All the examined sections presented a positive IM. We noticed heterogeneity of distribution of the Ki-67 positive cells with an intense nuclear marker/trace. The data regarding to the immuno-reactivity Ki-67 have shown that there are no differences in reactivity owing to the patients gender, the obtained values being very close. We noticed a significant difference of reactivity that was directly accorded to the patients age. Patients under 50 presented lesions accompanied by a slightly more intense expression of Ki-67 immunoreaction. On the gingival biopsies that were collected from patients with periodontal disease associated with prosthetic devices, there were no differences regarding Ki-67 immuno-reactivity in the epithelium according to the type of prosthetic work, but only among the patients with and without prosthetic devices.

In all the immunohistochemically analyzed cases we revealed a CD 31 immunoreaction constantly positive (but at a variable intensity) that occurred in the endothelial cells of the capillaries and neoformation vessels in the granulation tissue.

Analyzing the intensity of CD 31 immunoreaction in the forms of marginal periodontitis accompanied by bag and apical retraction of the epithelium, we noticed an intensely positive CD 31 immunoreaction in the superficial layers of the ulceration and also at the neoformation vessels, the immuno-coloration intensity decreasing towards the depths of the chorion.

Conclusions

By the morphological analysis of the periodontal components, we reported structural microscopic alterations closely correlated with macroscopic changes observed during the clinical examination. The fixed prostheses association with periodontal damage is closely related to the type of material used to carry out the dental prostheses. The pathological changes of the periodontal tissue are more profound in patients with prosthetic devices than in patients with no prosthetic works, and also the regenerating capacity of the damaged periodontal epithelium is more reduced in patients with dental prostheses than in those without any such devices.

After the morphological examination of the periodontal pocket, we did not notice any correlation between the severity of degenerative changes and the depth of the bag, the ulcerations of the side wall being also evident inside the superficial pockets [9 - 11].

We noticed that the regeneration and reepithelization seem to be delayed by: persistent inflammatory infiltrate in the epithelial spurs, the presence of the fibrinous, fibropurulent and hematic exudate on the surface of mucosa. On the studied casuistry we observed an association between the severity of periodontal lesions and proximity of crown material commonly used in dentistry.

In order to establish the degree of periodontal damage and prognostic criteria, we tried to correlate the proportion of collagen fibers and inflammatory infiltrate. According to the literature, inflammatory cellular infiltrate is the source of the main enzymes and cytokines, which can lead to "self-destruction" of the periodontal conjunctive tissue by releasing metallo-proteinases. An imbalance between the active metallo-proteinases and the inhibitors resulted in disintegration of the extracellular matrix.

We noticed a direct relationship between the proportion of inflammatory infiltrate /collagen fibers depending on the type of material adjacent to the periodontal tissue, the proportion being 27/2 for metal-alloy crowns, 2/22 in case of the ceramic crowns and 19/6 at composite resin crowns.

Since the healing process of the inflammation goes through an intermediate stage with granulation tissue proliferation, in the vascular phase, we appreciated the relative density of capillaries and fibroblasts neoformation. The relative density of fibroblasts and capillaries reached average values in the surrounding periodontium near the

composite crowns, while around the ceramic crowns we noticed the relative density for both capillary and fibroblasts.

By evaluating the positive substrates CD 31 we watched for the aspect of the vessels in lamina itself and the architecture of the microvessels which are component in the granulation tissue. Although we have not seen references in the literature for this purpose, we evaluated the immuno-histochemical reaction on the studied cases.

We highlighted an immunoreactivity CD31 constantly positive, but with a different intensity in the endothelial cells of capillaries, the level of micro-vessels from the granulation tissue area and also in the component cellular elements of the inflammatory infiltrate (lymphocytes, plasma cells, macrophages) from the areas of ulceration and gingival fibromucosa.

References

1. BOSMAN T. FRED, STAMKOVIC IVAN- Functional structure and composition of the extracellular matrix; Journ. of Pathology, Ed. J. Willey, Sons Ltd., (2003), 423-428;
2. CELIK MUZAFER, TUNCER S., EMEKLI UFUK - Histologic analysis of prefabricated vascularized bone grafts: an experimental study in rabbits, J. Oral Max. Facial Surg., 2000, 58: 292-295;
3. NISENGARD J. RUSSEL, NEWMAN MICHAEL G. (1994) - Oral microbiology and immunology, sec. Ed. Saunders comp. 1994 : 6-42;
4. NOGUERA MOREIRA A., CHIAPPEV., FERNANDEZCANIGGIA L., ALONSO C. PIOVANO S. Clinical and microbiological associations in chronic periodontitis, Acta Odontol Latinoam. 2004
5. AIBA T. A KENO N, KAVANE T. OKAMOTO H. HORIUCHI N. Matrix metalloproteinases-1 and 8 TIMP-1 MRNA levers in normal and diseased human gingivae EUR Journal Oral Scin 1996; 104: 562-569.
6. SCULEAN A. CHIANTELLA GC, WINDISCH P, DONOS N. Clinical and histopatologic evaluation of treatment of intrabony defects with an enamel matrix protein derivative (Emdogain). Int J Periodontics Restorative Dent 2000.
7. WEBB PP, MOXHAM BJ, BENJAMIN M. RALPHS JR, Changing expression of intermediate filaments in fibroblast and cementoblasts of the developing ligament of the rat molar tooth. J Anat 1996.
8. YUKNA RA, MELLONIG JT. Histologic evaluation of periodontal healing in humans following regenerative therapy with enamel matrix derivative. A 10 -case series J Periodontal: 2000; 71: 752.
9. *** Academy Report - The Pathogenesis of Periodontal Diseases. J Periodontol 1999; 70: 457-470.
10. ARMITAGE GC - Development of a classification system for periodontal diseases and conditions. Ann. Periodontol 1999; 4:1-6.
11. BERKOVITZ BK - Periodontal ligament: structural and clinical correlates. Dent Update 2004; 31(1): 46-54.
12. PAGE RC, OFFENBACHER S, SCHROEDER HE, ET AL - Advances in the pathogenesis of periodontitis: summary of developments, clinical implications and future directions. Periodontal 2000; 14: 216-248.
13. BOSSHARDT DD, LANG NP - The junctional epithelium: from health to disease. J Dent Res 2005; 84(1): 9-20.
14. RASPANTI M, CESARI C, DE PASQUALE V, OTTANI V, STROCCHI R, ZUCHELLI G, RUGGERI A - A histological and electron-microscopic study of the architecture and ultrastructure of human periodontal tissues. Arch Oral Biol 2000; 45(3): 185-192.
15. VAN DYKE T.E, SHEILESH D - Risk factors for periodontitis. J Int Acad Periodontol, 2005

Manuscript received: 27.01.2011