

Using Pig Tracheobronchial Corrosion Casts in Training of the Medical Students and Residents

OVIDIU BEDREAG^{1#}, ANDRA RAMONA BUT^{2#}, BOGDAN HOINOIU³, GRATIAN D. MICLAUS^{1,6}, SORIN URSONIU⁴, PETRU MATUSZ^{1*}, CAIUS IOAN DOROS⁵

¹“Victor Babes” University of Medicine and Pharmacy Timisoara, Department of Anesthesiology, 2 Eftimie Murgu Sq, 300041, Timisoara, Romania

²“Victor Babes” University of Medicine and Pharmacy Timisoara, Department of Anatomy, 2 Eftimie Murgu Sq, 300041, Timisoara, Romania

³“Victor Babes” University of Medicine and Pharmacy Timisoara, „Pius Branzu” Center for Laparoscopic Surgery and Microsurgery, 2 Eftimie Murgu Sq, 300041, Timisoara, Romania

⁴“Victor Babes” University of Medicine and Pharmacy Timisoara, Department of Public Health, 2 Eftimie Murgu Sq., 300041, Timisoara, Romania

⁵“Victor Babes” University of Medicine and Pharmacy Timisoara, Department of ENT, 2 Eftimie Murgu Sq., 300041, Timisoara, Romania

⁶Neuromed Diagnostic Imaging Centre, 43, 16 Decembrie Blvd., 3002018, Timisoara, Romania

The tracheal bronchus (TB) in man is described only as a rare anatomical variation, known as the “pig bronchus” or “bronchus suis”. The right-sided TB is normally present in swine. One of the employed method for the training of students and medical residents is the study of corrosion casts. A TB study was conducted on a total of 20 pig tracheobronchial corrosion casts. On the studied corrosion casts the distance between the origin of the TB to carina had an average of 45.1 ± 7.81 mm. The origin range of TB at the level of the right lateral trachea was between 37 and 61 mm above the carina. The mean angle that makes TB with the right lateral trachea was 40.29 ± 3.90 degrees with a variation of 15 degrees, ranging between 30-45 degrees. The increasing of the distance between the origin of TB and carina is associated with the decrease of the angle that makes TB with the right lateral trachea. Use of swine tracheobronchial corrosion casts with constant presence of TB, can compensate for lack of clinical material in training of medical students and residents.

Keywords: corrosion casts, tracheobronchial system; trachel bronchus, training

The tracheobronchial tree is a branched distribution system that carries air from the trachea to the lung parenchyma at the level of acini, for accomplishments of the gas exchange [1, 2]. The anatomic variations in the tracheobronchial system have an estimate incidence between 1 and 12% [3], including in almost of the cases: tracheal bronchus (TB), ectopic bronchus, accessory bronchus [4], and are most commonly asymptomatic.

TB, first described by Sandifort in 1785, is a congenital abnormality of the tracheobronchial tree, in which a displaced or accessory bronchus arises from the trachea superior to its bifurcation at the carina [2]. In a previous report [5] it has been revealed that the general prevalence of the TB is 0.1–2%. Most frequently, tracheal bronchus is located on the right side (fig. 1), to the junction of the middle and distal thirds of the right lateral trachea [6]. According to Wooten et al. [2] when the entire right upper lobe bronchus is displaced, it is known as a “true TB.” Studies of Ghaye et al. [3] reveal that the incidence of true TB is 0.2%. The left-sided TB appears infrequently, with a prevalence only of 0.3–1% [6]. In rare cases [7, 8] bilateral TB, with heterotaxy syndrome, are associated with major abnormalities of the thoracic and abdominal organs.

The right-sided TB is normally present in swine [9, 10]; in man it is described only as a rare anatomical variation, known as the “pig bronchus” or “bronchus suis”. The main clinical implication of a TB arises during endotracheal intubation [11]. The endotracheal tube can obstruct the TB, causing hypoxia, pulmonary atelectasis, or both [12].

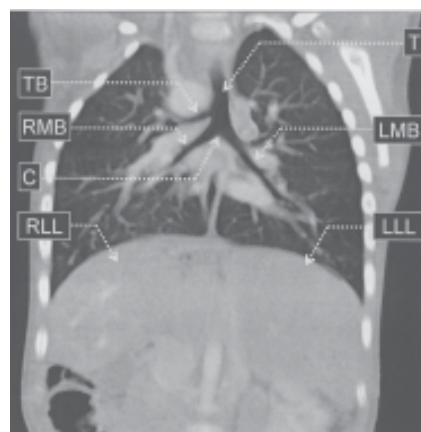


Fig.1. Coronal multiplanar rendering (MPR) images of thorax and upper abdomen of an heterotaxy syndrome with revealing the presence of right tracheal bronchus and a symmetrical horizontal liver. T – trachea, TB – tracheal bronchus, RMB – right main bronchus, LMB – left main bronchus, C – carin, RLL – right lobe of the liver, LLL – left lobe of the liver.

A TB also may occur in association with other congenital anomalies such as tracheal stenosis, tracheoesophageal fistula, and Down’s syndrome [2]. Typically, a right-sided TB is found at the junction of the middle and distal thirds of the right lateral trachea [de Wever, 2011]. A left-sided TB appears infrequently, with a prevalence of 0.3–1% [3].

The MDCT angiography is a powerful noninvasive examination used in order to evaluate the tracheobronchial

* email: matusz@umft.ro; Telefon 0729 016260

These authors contributed equally to this work

tree and demonstrating the special relationships of arterial and tracheal anomalies [13, 14]. The reduced prevalence of the TB explains the fact that generations of medical residents do not meet at least one case of such anomalies. Examination of pig tracheobronchial corrosion casts can substitute this inconvenience in training of medical residents.

Experimental part

In the present study, one used 20 domestic pigs (*Sus scrofa domestica*), with an average weight of 25 kg (21-32 kg), 14 male and 6 female, previously subject to achieve a kidney transplant experiment under general anesthesia. All animals were treated in accordance with the existing legislation harmonized under Directive 2010/63 / EU and recommendations of the Federation of European Laboratory Science Associations (FELASA). All experiments were approved by the Ethics Committee of the "Victor Babes" University of Medicine and Pharmacy, Timisoara. After the completion of the renal transplantation experiment, the animals were euthanized, using 0.3mL/kg T61 by intravenous injection. The neck and thorax of the 20 pig cadavers was collected at necropsy, and used to study the tracheobronchial system, focused on the study of tracheal bronchus.

Preparing for injecting of porcine anatomical parts followed a number of four steps:

- cross section of the neck with the reference posterior point the atlanto-occipital joint and anterior reference point the thyrohyoid membrane; placing in lower position of the cervical regions, for complete emptying of the supradiaphragmatic vascular system;

- anterior mediosagittal section of the cervical skin, up to the sternal manubrium, with infrahioidian muscles detachment; excision of thyroid cartilage; cricoid cartilage mobilization, by sectioning the postero-lateral connections;

- the cannulation of the proximal portion of the trachea with a transparent plastic tube, with a comparable diameter to the endoluminal diameter of cricoid cartilage and trachea;

- placing the cannulated anatomical piece in vertical axis.

Technovit 7143 plastic compound (Heraeus Kulzer GmbH, Wehrheim, Germany) (product based on methacrylate copolymers) was prepared for injection by combining a partially polymerized monomer base with a catalyst (Technovit Universal Liquid, Heraeus Kulzer GmbH) (methyl methacrylate and N,N-dimethyl-p-toluidine) a ratio of 1:1. A 50 mL syringe Luer-Lock was used to inject the solution under hand pressure until the entire tracheobronchial system was filled. The compound was allowed to polymerize for 24 h. To remove the pulmonary parenchyma and the surrounding tissues, the tracheobronchial block were submerged in technical hydrochloric acid for 5 days. Corrosion with hydrochloric acid was interrupted by daily washing under running water to encourage the disposal of the organic tissues. The tracheobronchial casts obtained were rinsed 24 hours in running water and finally measured with a manual caliper (Vernier Caliper) and photographed (Nikon D3, Tokyo, Japan, AF-S Nikkor Lens f/1.4G) (fig.2).

Results and discussions

In all 20 pieces of pig tracheobronchial corrosion casts was highlighted the tracheal bronchus, with origin at the right lateral trachea. On the studied corrosion casts the tracheal length (from the origin to the carina) had an average of 124.25 ± 4.56 mm, and the distance between

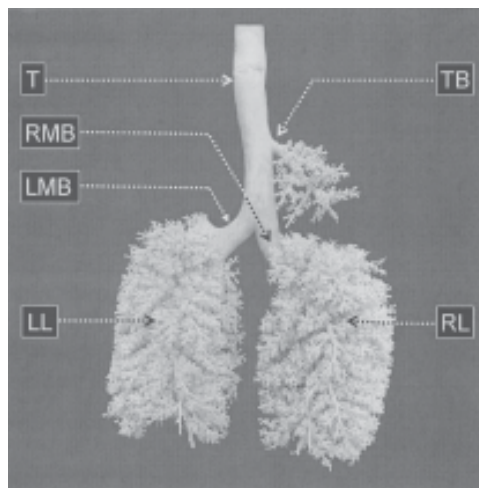


Fig.2. Corrosion cast of tracheobronchial system revealing the tracheal bronchus. Dorsal view. T – trachea, TB – tracheal bronchus, RMB – right main bronchus, LMB – left main bronchus, RL – right lungs, LL – left

the origin of the TB to carina had an average of 45.1 ± 7.81 mm. The origin range of TB at the level of the right lateral trachea was between 37 and 61 mm above the carina. The mean angle that makes TB with the right lateral trachea was 40.29 ± 3.90 degrees with a variation of 15 degrees between 30-45 degrees. Carina has an average angle of 50.02 ± 1.51 degree; the right main bronchus has an average slope of 168.65 ± 5.12 degree, and the left main bronchus of 141.4 ± 4.86 degree. The calculated values of morphological parameters at the level of tracheobronchial system are summarized in table 1.

Anatomical preparations study is one of the most important ways of training medical students and residents. Although MDCT angiography images are much easier to achieve, given the existence of adequate facilities [15], they do not provide three-dimensional images of the plastination preparations [16-18] and of the corrosion casts [19, 20].

The technology of tracheobronchial corrosion casts achievement is different, depending on the laboratory that it carried out, depending on whether the injection are performed *ex-situ* or *in-situ*, and according to the materials used for injection and corrosion. In principle, the results are similar.

Oldham and Phalen [21] as well as Henry [22] propose the achievement of tracheobronchial corrosion casts by injection with plastic mass of the dry tracheobronchial tree. In the first stage, mucus and blood within the tracheobronchial tree were allowed to flow out by washing with running water. This procedure was repeated 6 to 10 times, until most of the blood and secretions were cleared from the lungs and airways. After the water had drained from the tracheobronchial tree, the lungs were inflated and dried using compressed air directed into the trachea. The air flow was gradually increased until the lungs were inflated and remained inflated to near capacity until the lungs were completely dried. The selected polymer was poured into the trachea (placed in vertical axis) and allowed to flow into the trachea and lungs via gravitational forces. After 24 h, the entire injected pieces were placed in a vat of simmering to slowly boiling water for several hours, for the maceration of the lung and airway tissue from the cast material. If the organic tissue was not removed only with the high pressure water, the cast was submerged in a 10% sodium hydroxide solution until the remaining tissue was released. Finally the cast material were rinsed with water and allowed to dry.

| Morphological parameters measured | Mean \pm SD | Range |
|---|----------------------|-----------------------|
| Tracheal length from the origin to the carina | 124.25 \pm 4.56 mm | 118 - 133 mm |
| Distance between the origin of the tracheal bronchus and the carina | 45.1 \pm 7.81 mm | 37 - 61 mm |
| Transverse diameters of the trachea at the level of origin of the tracheal bronchus | 9.20 \pm 0.34 mm | 8.0 - 9.5 mm |
| Ventro-dorsal diameter of the trachea at the level of origin of tracheal bronchus | 7.78 \pm 0.31 mm | 7.2 - 84 mm |
| Transverse diameter of the trachea at the level of tracheal bifurction | 22.4 \pm 0.33 mm | 22.1 - 23.1 mm |
| Ventro-dorsal diameter of the trachea at the level of tracheal bifurction | 12.35 \pm 0.20 mm | 11.9 - 12.6 mm |
| Transverse diameters of the right main bronchus | 7.19 \pm 0.17 mm | 6.9 - 7.5 mm |
| Ventro-dorsal diameter of the right main bronchus | 8.29 \pm 0.18 mm | 8.0 - 8.6 mm |
| Transverse diameters of the left main bronchus | 7.09 \pm 0.14 mm | 6.8 - 7.3 mm |
| Ventro-dorsal diameter of the left main bronchus | 6.18 \pm 0.15 mm | 5.9 - 6.5 mm |
| Diameter at origin of tracheal bronchus | 6.13 \pm 0.15 mm | 5.9 - 6.5 mm |
| Length of tracheal bronchus | 46.86 \pm 4.28 mm | 38.9 - 56.3 mm |
| The angle of the tracheal bronchus and right side of the trachea | 40.29 \pm 3.90° | 30 - 45° |
| Carinal angle | 50.02 \pm 1.51° | 48 - 52° |
| Right tracheo-bronchial angle | 168.65 \pm 5.12° | 164 - 171° |
| Left tracheo-bronchial angle | 141.4 \pm 4.86° | 123 - 146° |

Table 1.
MEASUREMENTS OF THE
MORPHOLOGICAL PARAMETERS AT THE
LEVEL OF TRACHEOBRONCHIC SYSTEM

Kilpper and Dtid [23] made the injection of the tracheobronchial tree with the lungs immersion in a container filled with water. The entire casting procedure can be broken down into three steps: cleaning, deaeration, and injection. The first step, the cleaning, acts to remove the mucus and the blood of the tracheobronchial system. The deaeration, remove the air from the tracheobronchial system and leads collapse the lung parenchyma (similar to the atelectasis process). The injection of the plastic mass was done slowly because of the gravity force. The filling level of the tracheobronchial system was adjusted by setting the viscosity of plastic mass. After 24 h from the completion of injection, the injected anatomical piece was placed in a container filled with either concentrated potassium hydroxide or hydrochloric acid, for corrosion of the tissue. The corrosion will be completed within 24 h and the cast may be removed and rinsed in clean water. According with the author experience, a short soaking in either dilute acid or base will neutralize any remaining corrosion fluid and a final wash will complete the procedure.

Phalen et al. [24] recomand that before inject the tracheobronchial system *in-situ* it is important to realize several measurements of the functional residual capacity and the total volume of the tracheobronchial system. These measurements are used to determine the injection volume and to evaluate the final cast fidelity. The first step is represented by the saline solution which is slowly introduced into the tracheobronchial system using the pressure of a 5- to 10-cm column of saline solution. This process requires about 15 to 30 min to inflates the lungs, and prepares the whole tracheobronchial system for injection. This saline solution finally diffusing from the lungs, flows out of the thoracic by the additional laterothoracic incisions previously completed. The injection for a period of about one-hour is performed with automatic syringe at constant pressure. The volume of plastic mass has been

previously established based on measurements of the functional residual capacity of the tracheobronchial system. Usually, 12 h at room temperature are enough for curing of the cast before it is removed from the thorax. The injected anatomical piece is placed in a fresh one molar natrium hydroxide solution for about 24 h at room temperature for the purpose of tissue corrosion. A final washing with a weak acid solution is recommended.

In this study we performed pigs tracheobronchial system corrosion casts, following a simplified technique, but very effective, used in the Anatomical Laboratory of the „Victor Babes” University of Medicine and Pharmacy Timisoara (described above).

Comparative analysis of corrosion casts described in literature, and the technique used in the present study, show that:

- placing in lower position of the cervical regions after the cross section of the neck, ensure for complete emptying of the supradiaphragmatic vascular system, and eliminate the risk of obtaining incomplete injections of plastic mass;
- technovit 7143 plastic compound requires shorter curing time (6 h);
- corrosion of the organic tissues with technical hydrochloric acid (for 5 days) guarantees getting quality corrosion cast pieces.

Embryologically, the major structures of the humn tracheobronchial tree are usually complete by 16 weeks of gestation. According with Setty and Michaels [25] there are two theories on the development of tracheal bronchi:

- the first theory suggests that tracheal buds are present in utero and fail to regress during development;
- the second theory proposes that a tracheal bronchus results from a disturbance in embryogenesis.

Our studies on corrosion casts show that when the origin of the TB is located more proximal, the angle of the tracheal bronchus with the right side of the trachea decreases, and the length of tracheal bronchus increase. The left tracheo-

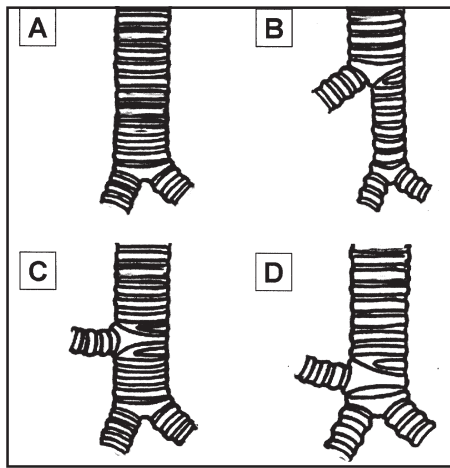


Fig.3. Schematic representation of the normal tracheobronchial system (A) and the three types of tracheal bronchus: Type I - displaced right upper lobe tracheal bronchus (B), Type II - supernumerary right upper lobe tracheal bronchus (C) and Type III - displaced right upper lobe tracheal bronchus as tracheal trifurcation (D)

bronchial angle have a variation much larger than the right tracheo-bronchial angle (left 23° , between $123 - 146^\circ$; only right 7° , between $164 - 171^\circ$).

The association of TB with other anomalies in children [26], motivates consideration especially of the second theory. The presence in pig of the TB is a normal condition.

TB is a term applied to any airway which arises from the trachea above the level of the main carina [12]. In medical papers there are many possible configurations of right-sided TB and right upper lobe bronchi. According to O'Sullivan [12] the right TB may be a displaced bronchus (situation where all three segmental bronchus arising from it with no right upper lobe connection to the right main bronchus), or the TB may consist of only a right upper lobe apical bronchus (situation where the anterior and posterior upper lobe bronchi arising from the right main bronchus).

Early report of Conacher [27] reveals three types of TB likely to be of significance to anesthesiologists (fig.3):

- type I - displaced right upper lobe TB;
- type II - supernumerary right upper lobe TB;
- type III - displaced right upper lobe TB as tracheal trifurcation.

If in the type I and type III of TB the presence endotracheal tube does not cause major disruption of the lung parenchyma ventilation, in type II, the presence endotracheal tube can lead to serious disorders of pulmonary ventilation.

Conclusions

The TB normally present in swine is described in man only as a rare anatomical variation. The main clinical implication of a TB arises during endotracheal intubation. Given the anatomo-clinical aspects of human medical practice, and given the low prevalence of human TB, the study of TB on pigs corrosion casts can contribute substantially in training of medical students and medical residents.

References

1. SEO JH, HWANG SH, KANG JM, KIM CS, JOO YH. Age-related changes of the larynx and trachea assessed by three-dimensional computed tomography in children: Application to endotracheal intubation and bronchoscopy. *Clin Anat.*, 2014, 27(3):360-364.
2. WOOTEN C, PATEL S, CASSIDY L, WATANABE K, MATUSZ P, SHANE TUBBS R, LOUKAS M. Variations of the tracheobronchial tree:

- Anatomical and clinical significance. *Clin Anat.* 2014 Epub ahead of print Jan 22. DOI: 10.1002/ca.22351.
3. GHAYE B, SZAPIRO D, FANCHAMPS JM. Congenital bronchial abnormalities revisited. *Radiographics.* 2001;21:105-119.
4. ABAKAY A, TANRIKULU AC, SEN HS, ABAKAY O, AYDIN A, CARKANAT AI, SENYIGIT A. Clinical and demographic characteristics of tracheobronchial variations. *Lung India.*, 2011, 28(3):180-183.
5. RITSEMA GH. 1983. Ectopic right bronchus: indications for bronchography. *AJR Am J Roentgenol* 140:671-674.
6. DE WEVER W. 2011. *The Respiratory Tract.* In Coche E, Ghaye B, de Mey J, Duyck P (eds.), *Comparative Interpretation of CT and Standard Radiography of the Chest.* New York: Springer. pp 247-268.
7. MING Z, LIN Z. Evaluation of tracheal bronchus in Chinese children using multidetector CT. *Pediatr Radiol.* 2007, 37(12):1230-1234.
8. MING Z, HONG S, BIAO J. Images in cardiovascular medicine. Asplenia syndrome with bilateral tracheal bronchi. *Circulation.* 2008, 118(2):196-197.
9. DOOLITTLE AM, MAIR EA. Tracheal bronchus: Classification, endoscopic analysis and airway management. *Otolaryngol Head Neck Surg* 2002;126:240-3.
10. COSTINIUK CT, VODUC N, DE SOUZA C. Pulmonary actinomycosis in a male patient with a tracheal bronchus. *Can Respir J.* 2011, 18(2):84-86.
11. WONG DT, KUMAR A. Case report: Endotracheal tube malposition in a patient with a tracheal bronchus. *Can J Anaesth.*, 2006, 53(8):810-813.
12. O'SULLIVAN BP, FRASSICA JJ, RAYDER SM. Tracheal bronchus: a cause of prolonged atelectasis in intubated children. *Chest.*, 1998, 113(2):537-540.
13. YILDIZ H, UGUREL S, SOYLU K, TASAR M, SOMUNCU I. Accessory cardiac bronchus and tracheal bronchus anomalies: CT-bronchoscopy and CT-bronchography findings. *Surg Radiol Anat.* 2006 Dec;28(6):646-649.
14. WATABNABE K, UESE K, HIGUCHI O, FUTATANI T, YOSHIMURA N, NAKAMURA T, ICHIDA F. Three-dimensional computed tomographic findings of bilateral tracheal bronchus. *Pediatr Cardiol.*, 2009, 30(1):87-88.
15. MATUSZ P, MICLAUS GD, PLES H, TUBBS RS, LOUKAS M. Absence of the celiac trunk: case report using MDCT angiography. *Surg Radiol Anat.* 2012 Dec;34(10):959-63.
16. SORA, MC., MATUSZ, P. General considerations regarding the thin slice plastination technique. *Clin Anat.*, 2010, 23(6):734-736.
17. SORA, MC., MATUSZ, P. Study of the vascular architecture of bones using the plastination technique. *Clin Anat.*, 2012, 25(2):258-259.
18. SORA, MC., JILAVU, R., MATUSZ, P. Computer aided three-dimensional reconstruction and modeling of the pelvis, by using plastinated cross sections, as a powerful tool for morphological investigations. *Surg Radiol Anat.*, 2012, 34(8):731-736.
19. MATUSZ P. Anatomical method for in situ studying of the renal vasculo-ductal elements. Preliminary report. *FASEB J.*, 2009 23:825.12
20. MATUSZ P., Left branch of the hepatic portal vein. Study on corrosion casts. *FASEB J.*, 2011 25:866.12
21. OLDHAM MJ., PHALEN, RF. Inflated, Dried Whole Lung Specimens. *Anat Rec.*, 1991, 231:286-292
22. HENRY RW. Silicone tracheobronchial casts J Int Soc Plastination, 1992, 6:38-40
23. KILPPER RW, STIDD PJ. A wet-lung technique for obtaining silastic rubber casts of the respiratory airways. *Anat Rec.*, 1973, 176(3):279-287.
24. PHALEN RF, YEH HC, RAABE OG, VELASQUEZ DJ. Casting the lungs In-situ. *Anat Rec.*, 1973, 177(2):255-263
25. SETTY SP, MICHAELS AJ. Tracheal bronchus: case presentation, literature review, and discussion. *J Trauma.*, 2000, 49(5):943-945.
26. MCLAUGHLIN FJ, STRIEDER DJ, HARRIS GB, VAWTER GP, ERAKLIS AJ. Tracheal bronchus: association with respiratory morbidity in childhood. *J Pediatr.* 1985; 106(5):751-755.
27. CONACHER ID. Implications of a tracheal bronchus for adult anaesthetic practice. *Br J Anaesth.* 2000, 85(2):317-320.

Manuscript received: 22.02.2014