

# Contributions Regarding the Assessment of Polymeric Materials Used in Complete Dentures by Thermographic Analysis

## Experimental study

LAURA IOSIF<sup>1\*</sup>, OANA ELENA AMZA<sup>2</sup>, ELENA PREOTEASA<sup>1</sup>, GHEORGHE AMZA<sup>3</sup>, CRISTINA TEODORA PREOTEASA<sup>4</sup>, CONSTANTIN DUMITRASCU<sup>3</sup>

<sup>1</sup> Dental Medicine University Bucharest, UMF "Carol Davila", Removable Prosthodontics, Complete Denture Department, 12 Ionel Perlea, 010209, Bucharest, Romania

<sup>2</sup> Dental Medicine University Bucharest, UMF "Carol Davila", Endodontics Department, 19 Calea Plevnei, 010232, Bucharest, Romania

<sup>3</sup> Politechnica University Bucharest, Materials Technology and Welding Department, Technological Systems Engineering and Management Faculty, 313 Splaiul Independentei, 060042, Bucharest, Romania

<sup>4</sup> Dental Medicine University Bucharest, UMF "Carol Davila", Oro-Dental Diagnosis, Ergonomics, Methodology of Scientific Research, 4-6 Eforie, 050035, Bucharest, Romania

*This study followed the value of thermographic investigation in interrelation of polymeric materials with oral mucosa in patients with complete dentures, respectively thermal surface changes at completely edentulous patients, with and without stomatitis, using ThermoCAM PM 350. Thermograms revealed an elevated temperature under the denture, thermal values corresponding to mucosal aspects (edentulous without dentures, dentures wearer, normal or congested mucosa, flabby ridge) and prosthetics (suction degree), with asymmetrical color distribution of the thermal field in oral mucosa, respectively denture surface. Polymeric material shows a similar temperature rise to the mucosa (thermal impression) and residual heat. Thus, thermography may be a method of polymer-oral status interrelation assessment in denture wearers, providing important information in prevention, diagnosis and treatment of oral diseases, acquired in relation to polymer dentures.*

*Keywords: polymeric material, oral mucosa, complete denture, thermography*

The polymethylmethacrylate (PMMA) was one of the first chemical products used as a biomaterial in several medical applications (such as bone cements, contact and intraocular lenses, bone fixation screws, material for filling cavities and bone defects, arthroplasty, cranioplasty, orthopedic prostheses). The first applications took place over 60 years ago [1, 2] but only in dentistry, in dentures' manufacture, replacing rubber-vulcanite bases from mid-nineteenth century [3, 4]. PMMA is still the main material used in dentures fabrication (removable partial or complete dentures and in implant-supported overdentures), with a consumption of approx. 400 t/year at the European level, corresponding to about 10 million manufactured dentures. The material is used especially in prosthetic treatment for geriatric patients, an increasing age segment [5-7], having a direct impact on their quality of life [8], also affected through physiognomical, masticatory, phonetic and psychosocial changes, which occur in the loss of all teeth [9].

In order to improve some technical characteristics it was tried replacing it with polystyrene, polyvinyl acrylate, polyamides (nylon) or photopolymerized resins (urethane dimethacrylate), but PMMA has shown better physical properties, biological tolerance and aesthetic properties [10]. A succession of new polymers and technologies (auto, thermo, baro, hydro, photopolymerization, polymerizing by injection or through alternative energy generated by microwave or visible light) have brought some improvements to conventional materials and technologies [11] obtaining parts with better physical and chemical characteristics (low porosity, color-stable, high strength, better adaptation), but still deficient

to achieve optimal standards for dental treatment, as far as new clinical aspects and therapeutic alternatives are concerned. Increase of material resistance was obtained by applying the layer polymerization technique or reinforcement with different inserts such as glass, carbon, aramid (Kevlar) or polyethylene fibers [12], fracture of acrylic bases being present in 60% of the denture wearers [13, 14]. It was tried to reduce microbial adhesion by introducing anionic groups such as phosphate groups [15], carboxyl groups [16], and antifungal drugs [17].

Through a large number and area of clinical situations, their practical and social implications, acrylic dental treatments raise a series of problems, often requiring their resumption, more treatment steps and new costs [18, 19], also through new materials and technologies with a new approach [20]. Contact surface in the acrylic bases plays a key role in denture-oral structures interface, through the existing roughness and asperities [21], biocompatibility, microbial adhesion, biodegradation via hydrolysis and enzymatic reactions [15, 21]. These unsolved issues may induce some changes in oral structures (the appearance of stomatitis, with frequency between 2.5 to 18.5%) by local cytotoxicity, genotoxicity, changes in the expression of some cytokines, or cellular growth factors, oxidative stress induction on cellular level [22], mechanical trauma or microbial aggression, more common aspects in patients with associated hyposaliva [23] and pH changes (in general diseases, medications, stress context), can affect treatment and quality of life, especially in the elderly [24], but not limited only to them.

Quite recent, dispersed studies are present in this literature field, regarding surface quality, dimensional

\* email: lauraiosif@yahoo.com

changes and deformation during the manufacturing process, uncertain biological properties [22, 25], cytotoxic effects [26, 27], microbial load [19] and stomatitis occurrence in acrylic denture wearers [28, 29]. Deficiencies such as porosity have direct clinical impact on the biological environment contact, especially in maxillary oral mucosa, its coverage of the acrylic material surface being almost double to the mandibular mucosa one, where the self-cleaning and immunological saliva actions compensate the destructive effects of polymers. This may explain the increased frequency of denture stomatitis [30, 31], infectious-inflammatory disease generated mainly by fungi belonging to the *Candida* genus [22, 32-36] in the oral mucosa that comes in contact with the maxillary denture polymer [37]. Several researches describe the biofilms structure in dentate patients, much less instead refer to the mucosal or salivary microflora in complete edentulous, and even less in complete denture wearers [38, 39]. Nonpathogenic microbial flora, especially the fungal and anaerobic species, currently present in the oral area in completely edentulous without dentures as well as other oral manifestations, can not stay unaffected by the interaction with the polymer environment, especially through its changes in time, with exceeding the limit between pathogenic and non-pathogenic, between opportunism and colonization [40].

Starting from the polyacrylate deficiencies used in dentistry and oral manifestations, from data accumulated until now, the advances in medicine and the new possibilities offered by current technologies of investigation, we recommend in this study to assess the possibilities that thermography as method of investigation of the oral mucosa polymer interface in the denture wearers can offer. The originality lies in highlighting the temperature change underneath the polymeric denture using modern technology, as a result of microbial fermentation of these materials, the finding being so far argued, based on clinical observations.

## Experimental part

### *Materials and methods*

To assess the possibilities of using the thermographic method by in vivo exploration regarding the contact between the biological environments (represented by the maxillary oral mucosa) with the polymer contact surface, in denture wearers, we conducted a pilot study in two clinical situations of bimaxillary edentulism, with different oral status. The study determined the intraoral temperature in relation with the polymeric denture, respectively on the palatal vault mucosa and the internal surface of the maxillary denture, immediately after its removal from the mouth.

This study was conducted at the Faculty of Dentistry, Department of Mobile Prosthetics, Complete Denture Discipline, Carol Davila University of Medicine in Bucharest, in partnership with the Department of Materials and Welding Technology, Faculty of Engineering and Technological Systems Management, UPB Bucharest.

Use of thermography in medicine is known especially in assessing the presence of tumors, but for the removable prosthodontics it is a new, interdisciplinary method, with literature references practically absent regarding the investigation of oral mucosa in denture wearers. Therefore we consider opportune to emphasize notions of terminology used in thermography, as follows.

Infrared thermography is a technical procedure that allows obtaining by using a proper device, the thermal image of a thermal scene observed in a field of infrared

spectral range. By thermal image we mean a structured distribution of representative data of infrared radiation from a thermal stage, and by thermal stage a part of the space-object that is observed with infrared thermography equipment.

Thermographic examination involves observation, measurement and interpretation of thermal scene characteristics using devices called thermal radiation detectors.

Thermography system refers to all devices that allow receiving and processing a thermal radiation image.

The thermogram refers to the result in temperature transcript of one or more maps of luminance (luminance - brightness of objects measured in  $\text{cd/m}^2$ ); encoded image of a thermal scene.

Emissivity or emission factor is a dimensionless number with values between 0 and 1, representing the ratio between the total power emission of a certain body and the black body.

The black body is a perfect body that completely absorbs the received thermal radiation, also being the best transmitter [41].

In order to achieve the objectives, the pilot study was conducted in 4 stages:

Stage 1 - selecting and assessing the characteristics of thermography equipment.

Stage 2 - inclusion in the study of two different oral mucosa statuses in two different prosthetic situations.

Stage 3 - analysis, by thermographic investigation, of the biological environment represented by oral mucosa, followed by the polymeric substrate represented by complete maxillary denture.

Stage 4 - analysis, interpretation and association of thermographic data with clinical ones.

Infrared camera ThermoCAM PM 350 Inframetric was chosen and used for thermography. Its technical characteristics mention the sensitivity values under  $0.1^\circ\text{C}$ , 12-bit digital resolution, and temperature measurement range  $-10 \dots 450^\circ\text{C}$ , memorizing range  $-40 \dots +70^\circ\text{C}$ , maximum measured temperature  $1500^\circ\text{C}$  [42]. In order to obtain accurate images, and also limit possible thermal artifacts, a protocol with strict procedures was established and followed, regarding the development environment of the thermography itself:

- choosing a suitable room in size to maintain a uniform ambient temperature;
- providing air-conditioning with an even, constant ambient temperature in the procedure room, keeping it in the range  $20\text{-}24^\circ\text{C}$ , range designed to provide a stable thermo-physiology, i.e. thermal comfort for the investigated patients;
- maintaining air humidity at  $45 \dots 60\%$ ;
- excluding any air drafts from the room.

The investigation was performed in clinostatic position for both patients, with adequate support to the cephalic extremity [43]. Previous to the thermography, an automatic calibration of the thermocam was done.

The time of entry into operation and auto calibration takes about 10 min due to the cooling system of the thermocam. The following parameters have been manually adjusted (manual calibration stage):

- choosing the specific emissivity of the human body, namely  $\epsilon = 0.98$ , for  $\lambda > 2 \text{ mm}$  [44, 45], specifying that the emissivity is not a fixed value, variation depending on certain factors related to surface (humidity/temperature);
- humidity;
- ambient temperature;
- color palette;

- manual focus of the image;
- use of subrange of the temperature from -10°C to 65°C.

In the second stage we selected two situations of bimaxillary edentulism, based on the following inclusion criteria:

- absence of any systemic disease;
- absence of any endocrine changes such as those of pregnancy, menopause, respectively hormonal contraceptive medication;
- absence of any metabolic disorders;
- absence of any fever conditions [46].

Patients were informed about new methods of investigation and informed consent was obtained. In the recruited subjects distinctive aspects were identified through clinical methods, present at the maxillary oral mucosa level, considered representative, as follows:

- mucosa without any pathological changes in the non-denture wearer patient, with a negative microbial test;
- mucosa with Newton type II stomatitis, in the complete denture wearer, showing positive cultures of *Candida*, microbiologically highlighted (through prelevation from this area and cultivation in the specific Sabouraud-Dextroze medium (2% Agar).

Newton type II denture stomatitis is characterized by a diffuse erythema corresponding to the mucosa related to the denture base. Congestive areas are restricted to the mucosa surface that comes in contact with the unpolished impression surface of the polymer denture [47]. A pre-investigation protocol was followed for the patient, thus:

- subjects were not exposed to extreme thermal conditions (such as physical effort, exposure to sunlight);
- 24 h prior to investigation subjects were informed not to perform the following type of treatments: acupuncture, electrotherapy, ultrasound, or anti-inflammatory drugs;
- nicotine consumption, alcohol, coffee and tea were excluded in the procedure day [41];
- subjects did not eat or drink 60 min before the proceedings, in order not to influence/change the intraoral thermal values [48, 49];
- the dentures wearer subject was indicated not to remove them from the oral cavity for 12 h, and not to clean the maxillary denture 24 h prior the investigation;
- the subject without dentures was indicated not to clean the oral cavity 24 h before the procedure.

The third stage of the experiment consisted of thermographic investigations of the oral mucosa and the impression surface of the maxillary denture in the denture wearer, after its removal from the oral cavity. Before the examination, the detector was cooled to start the operating mode, with an integrated microsystem operating on Stirling principle (with helium pump) [44].

Thermography started 30 min after the presentation of subjects in the consultation room, time designed to thermally accommodate them to the ambient temperature. Also, subjects were asked not to lean on other objects that could influence body heat (chair, wall, etc.).

Sterile, plastic oral spreaders were applied in the oral cavity, and both dentures were removed. Parameters



Fig. 1. Thermography of maxillary oral mucosa



Fig. 2. Thermography of impression side of polymer denture base

related to emissions, the distance to the investigated areas were set in the configuration menus on the infrared camera. A thermographic scan of the oral mucosa followed, the lens oriented at an angle of approx. 70° to the palatal vault plan, from a distance of 25-30 cm between the front lens of the camera and the examined area (fig. 1), followed by the polymeric denture, the lens oriented at an angle of approx. 80° from its inner surface, from a distance of approx. 25 cm (fig. 2). The scans took about 1 minute each.

The fourth stage of the experiment consisted in analysis and correlation of the thermal data with the clinical ones. Thermal images are the result of thermal radiation heat conversion (heat emitted from a surface, i.e. a body) in temperature values. During the experiment we analyze thermal images in parallel with the visible ones in order to correlate and identify areas of interest. Visible color palettes in the thermograms were selected differently by the thermocam, the latter having the opportunity to 'seize' automatically minimum and maximum values of the thermal scene. It amounted to a wide temperature range of between 28.9-37.4°C, and interpretations were made regarding the thermal values obtained for each of the examined areas. In other words, we observed and evaluated the thermal values, not colors themselves. Also in this stage, thermal images were saved in TIFF format on PCMCIA card, specific software of the ThermaGram, in order to analyze and interpret them, optimizing the used temperature range, adapted to the color palette. The same images were then transferred to a computer for viewing (fig. 3, 4), analyzing, processing, respectively storage. After processing we obtained thermal images and the hottest points of practical interest were shown.

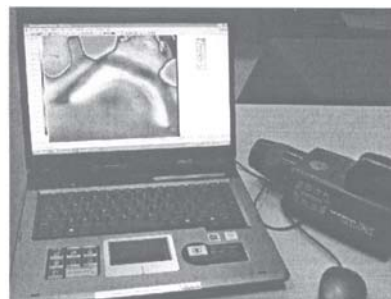


Fig. 3. Thermal image of the superior oral mucosa on the monitor

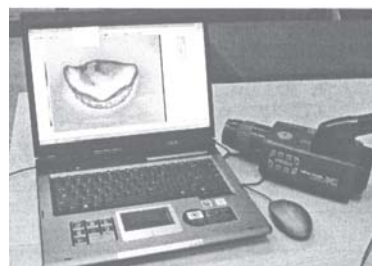


Fig. 4. Thermal image of the polymer denture on the monitor



## Results and discussions

Electronic thermography offers control and possibility of changing color sequence by the operator in order to obtain a maximum of information. Thus, a color scale appears in each image. Colors are presented in decreasing order from values of maximum heating, to those which encode the lowest thermal values. The colors themselves have no intrinsic value: red, for example, is not automatically interpreted as a high temperature zone; the operator sets the sensitivity of the color scale. In normal situations, the human body radiates heat after a symmetrical pattern. Any deviation from this symmetry indicates the presence of functional abnormalities, but not anatomical ones for the examined area. Our experiment focuses on visible clinical aspects (normal or pathological biological environment, namely the polymer substrate) and on the related heat. Thermal information is presented as point by point images, without any mechanical decomposition of the objects/surfaces images.

Comparative evaluation of mucosa thermograms (fig. 7, 8) with images visible (fig. 5, 6), respectively thermograms performed for the complete maxillary denture (fig. 9-11) at different moments after its removal from the oral cavity, reveal different clinical aspects corresponding to the maxillary support surfaces, in direct contact with the polymer bases of the dentures, associating some thermal images, respectively different temperature values.

Thus we could observe the following:

- in the denture wearer we found asymmetries in the distribution of colors belonging to the two halves right/left of the examined mucosal surface; thermal values recorded a maximum for the frontal ridge area, respectively for the lateral left one. Between the average temperatures recorded at the ridge mucosa and the palatal vault one in this subject resulted a difference in temperature of approx. 1.4°C;

- a thermal plus on the entire palatal mucosa in the subject without dentures respectively on the edentulous ridge mucosa and the third anterior of palatal vault mucosa

in the denture wearer is present. The difference may be correlated with the breathing in the prosthetic untreated patient and dentures effect (of polymers, microbial action and occlusal pressure exercised on the ridge, the primary support area) in the one wearing dentures;

- in the patient without dentures the thermal field reveals uniformity, i.e. slightly higher temperature for the palatal vault mucosa compared to that recorded at the ridge level, but lower in value than in the denture wearer with denture stomatitis. Both the visible image (fig. 6) and the maxillary oral mucosa thermogram at this subject (fig. 8) show significantly different characteristics from the denture wearer patient: lower temperatures with symmetrical left/right surfaces in terms of caloric values, uniform thermal field. The difference between the average temperature recorded at the crest mucosa and the palatal vault was 0.2°C. For the edentulous ridge area an average temperature of 34.8°C was recorded, and for the palatal vault area a value of 35°C, temperatures which have been assigned the colors blue, green from the color palette;

- at the complete maxillary denture wearer with denture stomatitis Newton type II (fig. 5), areas of congestion are obvious as pathophysiological phenomenon resulted from the connection with the polymeric dentures (fig. 12). Thermal field reveals reduced uniformity (fig. 7), with an average temperature of 36.6°C for the edentulous ridge areas and approx. 35.2°C for the palatal vault mucosa. To the frontal ridge, clinically flabby with hyperemic surfaces due to high metabolic rates, white-yellow areas correspond to the thermal image, representing a thermal maximum;

- the maxillary denture thermography, made in seconds after removal from the oral cavity (fig. 9) reveals different heat values, a heat climax of the entire surface corresponds to the white areas from the frontal ridge (between the two canines) and the left side ridge, namely 35.4°C. Regarding the mucosal temperature (fig. 7), we observe that at the palatal vault level, the temperature is higher in the third anterior. Marginal seal - suction part of the maxillary

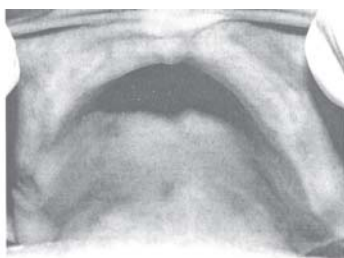


Fig. 5. Clinical image of the maxillary oral mucosa covered by the denture

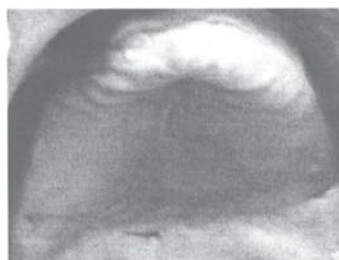

Fig. 6. Maxillary oral mucosa aspect without contact to the polymer environment

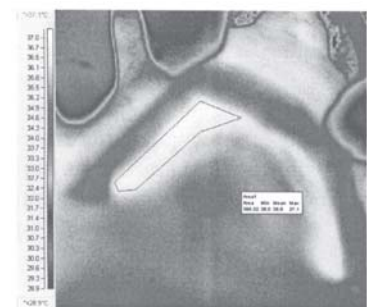


Fig. 7. Maxillary oral mucosa thermogram at the complete denture wearer

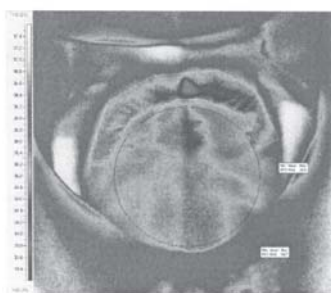


Fig. 8. Maxillary oral mucosa thermogram at the patient without dentures

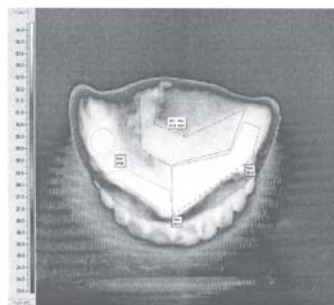


Fig. 9. Thermogram of the denture impression side, immediately after its removal from the oral cavity

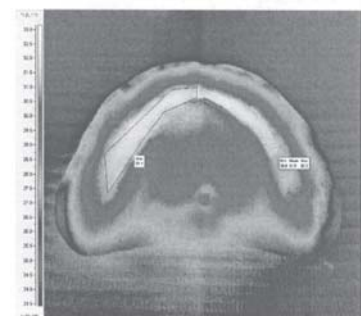


Fig. 10. Thermogram of the denture impression side 10 min. after its removal from the oral cavity

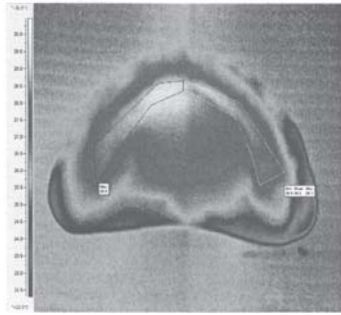


Fig. 11. Thermogram of the denture impression side 11min. 30 s after its removal from the oral cavity




Fig. 12. Clinical aspect of the polymer denture inner side

denture, shows lower heat values, uniformly distributed, respectively constant throughout its inner edge;

- the maxillary denture thermography 10 min after its removal from the oral cavity shows a non-uniform thermal field, i.e. asymmetric, being noticed a drop in maximum temperature by 3.2°C, reaching a value of 32.2°C (fig. 10) compared with maximum viewed on the first thermogram. (fig. 9). The impression denture surface corresponding to the frontal and left side ridge still shows high heat value compared to the rest of the prosthetic area, these values being associated with the yellow color on the palette. Marginal zone, with lower heat values than those previously recorded, presents the same symmetry, i.e. uniform distribution. On this image we can notice more easily than in the previous the close match of thermal values registered to the mucosal substrate (ridge and a third anterior of the arch) with the ones on the impression surface, which thus obtains a negative thermal copy aspect to the first thermography surface;

- thermography performed 1min 30s after the previous one (fig. 11) reveals a decrease of the maximum heat for the entire polymeric mucosal surface by 2.7°C, reaching 29.5°C. The thermal field asymmetry is marked by a yellow mark, corresponding to the heat maximum located at the denture's internal surface, associated to the left side of the frontal ridge. We also noticed the same thermal characteristics for the marginal seal zone, as in the previous thermograms.

## Conclusions

Besides the use of thermography in tumor diagnosis, its recent introduction in assessing mucosa practice in relation to removable dentures by the authors [41] represents a new approach that started from the observation that each individual has its own oral thermal image, similar to the uniqueness of fingerprints.

In the presence of polymeric denture bases, thermal changes occur in the oral mucosa that can be highlighted on the thermograms (as level and range of temperature). Polymeric material itself has a low thermal remanence [42] taking over and storing for a significant period of time the temperature of the contact surface, fact demonstrated by thermal values viewed on the maxillary denture thermograms after the removal from the prosthetic field. With a low conductivity, respectively minimum heat loss, PMMA preserves high temperature in the mucosa under dentures. Thermograms have shown increasing temperature in relation to the biological environment covered with PMMA, but also the residual heat of the material, with a distribution that can be correlated with clinical manifestations of the removable prosthesis (presence of denture stomatitis).

Sensing the earliest and smallest signal disturbances in the form of heat, thermography is a method that predicts clinical expression of the inflammation (consequence of dysfunctional pressure or microbial action), in the oral tissues covered by the polymeric material, capturing first changes in the tissue structures [50]. The basic principle for evaluating the functional status and/or organic changes is represented by the relative increase or decrease of thermal emission and disturbance of symmetry or local architectonics.

In interpreting the results of the experiment, the presence of asymmetry, uniformity lack of the thermal field and temperature differences of more than 1°C between areas of interest recorded in the denture wearer patient, visible both on the mucosal and acrylic piece thermograms, reported at the subject without dentures, orients to show not only the growth but the maintenance of high temperature under acrylic base, i.e. the initiation of pathological changes.

We can affirm that this experiment allows the recognition of the thermography role of polymeric substrate represented by mobile oral prostheses in relation to the underlying mucosa by:

- monitoring the prosthetic treatment, the efficiency control of established treatments or pathological process in relation with polymer bases;

- opportunity of monitoring the quality of polymeric material in time, until the appearance of aging and degradation phenomena that are characteristic and visible directly;

- soft tissue inflammation such as oral mucosa, which comes into direct contact with the polymeric material, doesn't exclude the initiation of changes in the mucosal substrate by maintaining high temperatures under the dentures, that favor microbial growth;

- prevention, location and explanation of denture stomatitis etiopathogenesis, with the intention of elaborating in the future of thermal maps with interpretation patterns for the acrylic denture wearers, indicating sensitive areas, with reference to the degree of microbial adhesion to the polymer parts;

- higher temperature in the frontal ridge, soft tissue inflammation in direct relation with the polymeric material, does not exclude the initiation of changes in bone support substrate in a quantitative or qualitative sense, with a flabby ridge aspect, which can then be highlighted;

- potential correlation (that authors aim to investigate in the future) between the increase of mucosal temperature values and degree of roughness, respectively of denture suction, with direct implications in the equilibrium conception of the prosthetic piece and way/rhythm of wearing by patients;

- thermal field obtained by thermography in different stages of denture wearing can provide information on selective processing of some prosthetic surfaces, respectively correlate the suction degree with the functional role of each denture area.

Thus, results of the experiment entitle to further study of dentures made of PMMA using infrared thermography, to reveal the material behavior in the oral environment and its interactions in vivo, to optimize the attributes and respectively limit the effects of its deficiencies.

## References

1. FREITAS OLIVEIRA PARANHOS de H., ORSI I.A., ZANIQUELLI O., CANDELAS ZUCCOLOTTO M.C., MAGALHAES F., *Braz J Oral Sci*, **7**, nr. 26, 2008, p. 1580
2. CONSANI R.L.X, FERRAZ MESQUITA M., CONSANI S., SOBRINHO L.C., SOUSA-NETO M.D., *Braz Dent J*, **17**, nr. 1, 2006, p. 53
3. PHOENIX R.D., MANSUETO M.A., ACKERMAN N.A., JONES R.E., *J Prosthodont*, **13**, nr. 1, 2004, p. 17
4. ROMINU M., BRATU D., LAKATOS S., FLORITA Z., *Polymerisation in dentistry*, Brumar, Timisoara, 2000.
5. MUZIKA B.C., DEHLER K.R., BRANNON R.B., *Dent Abstr J*, **55**, nr. 2, 2010, p. 94
6. ETTINGER R.L., *J Am Dent Assoc* 2007, **138**, 5S-6S
7. PREOTEASA E., MELESCANU-IMRE M., PREOTEASA C.T., MARIN M., LERNER H., *Rom J Morphol Embryol*, 2010, **51**, nr. 2, 2010, p. 309
8. CHENG Y.Y., LI J.Y., FOK S.L., CHEUNG W.L., CHOW T.W., *Dent Mater J*, **26**, nr. 9, 2010, p. e211
9. PREOTEASA E., PREOTEASA C.T., MELESCANU-IMRE M., IOSIF L., TANCU A.M., NABIL S.A., *Rev Med Milit*, CXIII, nr. 4, 2010, p.11
10. FRAZER R.Q., BYRON R.T., OSBORNE P.B., WEST K.P., *J Long Term Eff Med Implants*, **15**, nr. 6, 2005, p. 629
11. GOMES M., BROILO J.R., WALBER L.F., MACCARI A.P.C., SHINKAI R.S.A., *J. Appl. Oral Sci*, **12**, nr. 4, 2004, p. 322
12. PREOTEASA E., GAVAN M., PREOTEASA C.T., MURARIU-MAGUREANU C., *Acrylic resin reinforcement by different fibers and particles. Clinical and experimental studies*. Cermaprint, Bucuresti, 2009, p. 169-180, 198, 238-242, 300-323
13. VALLITTU P.K., LASSILA V.P., LAPPALAINEN R., *Acta Odontol Scand*, **51**, nr. 6, 1993, p. 363
14. UZUN G., HERSEK N., TINCER J., *Prosthet Dent*, **81**, nr. 5, 1999, p. 616
15. DHIR G., BERZINS D.W., DHURU V.B., PERIATHAMBY A.R., DENTINO A., *J Prosthodont*, **16**, nr. 6, 2007, p. 465
16. PARK S.E., CHAO M., RAJ P.A., *Int J Dent*, **2009**, 2009, ID 841431
17. AMIN W.M., AL-ALI M.H., SALIM N.A., AL-TARWANEH S.K., *Eur J Dent*, **3**, nr. 4, 2009, p. 257
18. N'DINDIN A.C., N'DINDIN G.B., AMANI S.R., MORENAS M., *Odonto-Stomatologie Tropicale*, **92**, decembre, 2000, p. 13.
19. GRIMONSTER J., *Acta Odontol Scand*, **203**, 1998, p. 299
20. PREOTEASA E., MURARIU-MAGUREANU C., IONESCU E., PREOTEASA C.T., *Rev Med Chir Soc Med Nat Iasi*, **111**, nr. 2, 2007, p. 487
21. ZAMPERINI C.A., MACHADO A.L., VERGANI C.E., PAVARINA A.C., GIAMPALO E.T., DA CRUZ N.C., *Arch Oral Biol*, **55**, nr. 10, 2010, p. 719
22. BETTENCOURT A.F., NEVES C.B., de ALMEIDA M.S., PINHEIROA L.M., ARANTES e OLIVEIRA S., LOPES L.P., CASTRO M.F., *Dent Mater J*, **26**, nr. 5, 2010, p. e171
23. TORRES S.R., PEIXOTO C.B., CALDAS D.M., *Med Mycol*, **41**, nr. 5, 2003, p. 411
24. SILVERMAN S.jr, *J Am Dent Assoc*, **138**, nr. 1, 2007, p. 41s
25. BRATU D., IEREMIA L., URAM- TUCULESCU S., *Clinical and Technical Bases of the Complete Denture*, Imprimeria de Vest Oradea, Timisoara, 2003, p. 338
26. LIU Y., ARVIDSON K., ATZORI L., SUNDQVIST K., SILVA B., COTGREAVE I., *J Dent Res*, **70**, nr. 7, 1991, p. 1068
27. FRANZ A., KONIG F., SKOLKA A., SPERR W., BAUER P., WATTS D.C., SCHEDULE A., *Dent Mater J*, **23**, nr. 11, 2007, p. 143
28. de OLIVEIRA C.E., GASPAROTO T.H., DIONISIO T.H., PORTO V.C., VIEIRA N.A., FERREIRA SANTOS C., SOARES LARA V., *Int J Prosthodont*, **23**, nr.2, 2010, p. 158
29. YOUNG B., JOSE A., CAMERON D., MC CORD F., MURRAY C., BAGG J., RAMAGE G., *Int J Prosthodont*, **22**, nr. 5, 2009, p. 488
30. PINTO T.M.S., CLARO NEVES A.C., PEREIRA LEO M.V., CARDOSO JORGE A.O., *J Appl Oral Sci*, **16**, nr. 6, 2008, p. 385
31. CROSS L.J., BAGG J., OLIVER B., WARNOCK D., *J Antimicrob Chemother*, **45**, nr.1, 2000, p. 95
32. ZHOU L., TONG Z., WU G., FENG Z., BAI S., DONG Y., NI L., ZHAO Y., *Arch Oral Biol*, **55**, nr. 6, 2010, p. 401
33. HAHNEL S., Ettl T., GOSSAU M., ROSENTRITT M., HANDEL G., BURGERS R., *Arch Oral Biol*, **55**, nr. 5, 2010, p. 391
34. PUSATERI C.R., MONACO E.A., EDGERTON M., *Arch Oral Biol*, **54**, nr. 6, 2009, p. 588
35. NALBANT A.D., KALKANCI A., FILIZ B., KUSTIMUR S., *Yonsei Med J*, **49**, nr. 4, 2008, p. 647
36. CHANDRA J., PATEL J.D., LI J., ZHOU G, MUKHERJE P.K., MC CORMICK T.S., ANDERSON J.M., GHANNOUM M.A., *Appl Environ Microbiol*, **71**, nr. 12, 2005, p. 8795
37. van NOORT R., *Introduction to dental materials*, 2-nd edition, Mosby, 2002, p. 211
38. SACHDEO A., HAFFAJEE A.D., SOCRANSKY S.S., *J Prosthodont*, **17**, nr. 5, 2008, p. 348
39. PREOTEASA E., IONESCU E., BANCESCU G., BANCESCU A., PREOTEASA C.T., *Bacteriol Virusol Parazitol Epidemiol*, **50**, nr. 1-2, 2005, p. 27, 2005
40. BUIUC D., NEGUT M., *Clinical microbiological dissertation*, 3-rd edition, Medicala, Bucharest, 2009, p. 25-27, 966
41. PREOTEASA E., IOSIF L., AMZA O., PREOTEASA C.T., DUMITRASCU C., *J Optoelectron Adv M*, **12**, nr. 11, 2010, p. 2333
42. MIHAI A., *Infrared thermography: fundamental principles*, Tehnica, Bucharest, 2005, p. 243-244
43. MC GLOTHLIN J.D., JENSEN PA., FISCHBACH T.J., HUGHES R.T., JONES J.H., *Scand J Work Environ Health*, **18**, nr. 2, 1992, p. 103
44. JAFARZADEH H., UDOYE C. I., KINOSHITA J.-I., *J Endod*, **14**, nr. 12, 2008, p. 1435
45. BUZUG M., HOLZ D., KOHL-BEREIS M., SCHMITZ G., *Non-Standard Medical Imaging Modalities*, in: U. Hartmann et al. (Eds.), *Aktuelle Methoden der Laser- und Medizinphysik*, VDE, Berlin, 2005, p. 22-27
46. MOORE J.R., WATTS J.T.F., HOOD J.A.A., *Eur J Orthod*, **21**, 1999, p. 249
47. IOSIF L., PREOTEASA E., MURARIU-MAGUREANU C., *Rev Med Milit*, **CXIII**, nr. 1, 2010, p. 18
48. YOUNGSON C.C., BARCLAY C.W., *Clin Oral Investig*, **4**, nr. 3, 2000, p.183
49. ENGELEN L., de WIJK R.A., PRINZ J.F., van der BILT A., JANSSEN A.M., BOSMAN F., *Eur J Oral Sci*, **110**, nr. 6, 2002, p. 412
50. TIPA R., BALTAG O., *Romanian J Phys*, **51**, nr. 3-4, 2006, p. 371

Manuscript received: 23.02.2001