

# Morphological Variability of the Hepatic Portal Vein Lateral Branches

## Study on corrosion casts

AGNETA MARIA PUSZTAI<sup>1</sup>, SORIN DUMITRU IOANOVICIU<sup>2\*</sup>, PETRU MATUSZ<sup>1</sup>

<sup>1</sup> Victor Babes University of Medicine and Pharmacy Timisoara, Department of Anatomy, 2 Eftimie Murgu Sq, 300041, Timisoara, Romania

<sup>2</sup> Victor Babes University of Medicine and Pharmacy Timisoara, Department of Internal Medicine I, 2 Eftimie Murgu Sq, 300041, Timisoara, Romania

*The liver segmentation is mainly determined by the intraparenchymatous distribution of the vascular and ductal hepatic elements; from this, the hepatic portal vein (HPV), is the most important afferent element. The lateral branches (LBr) are serving left lateral division (LLD) of the liver and present a moderate morphological variability. On a total of 160 pieces of liver corrosion casts, one examined the intraparenchymal distribution of portal LBr and the segmentation of LLD. Regarding the intraparenchymal distribution of the portal branches in the LLD of the liver, we showed two distinct morphological types: Type I (89.375% of cases) in which from the umbilical part of the left branch arise two LBr; Type II (10.25% of cases) in which from the umbilical part of the left branch arise three LBr. Knowledge of these morphological types of portal LBr is important for clinical and surgical practice.*

*Keywords: corrosion casts; hepatic portal vein; lateral branches; variability; morphological typologies*

History of the intraparenchymatous studies of the liver and the liver segmentation span three centuries. The first description of the liver segmentation has been described by Rex in 1888 [1]. The first intra-parenchymatous study revealing the arrangement of the vascular and ductal elements of the right and left lobes of the liver was that of Cantlie in 1898 [2]. Based on anatomical and surgical researches, Couinaud in 1957 [3] made the most complete description of liver parenchymal segmentation, taking the elements of afferent pedicle landmark structures for segmentation. Based on this description, Terminologia Anatomica [4] homologates the liver segments in number eight, grouped in four parenchymal divisions. The left lateral division (LLD) is composed of two segments: superior lateral segment (II) and inferior lateral segment (III).

Matusz et al., [5] analyzed the evolution of research on liver segmentation, and highlighted the great variability of parenchymal LLD. The presence of a single segment in the LLD was described by: Hjörstjo (1948) Diaconescu (1963) and Nomina Anatomica (1965). The LLD with two segments has been described by: Healey (1953), Couinaud (1954 and 1957), Reiferscheid (1957), Ciobanu (1958), Lanz and Wachsmuth (1993) and Terminologia Anatomica (1998). The only author who described three segments in the LLD was Platzer (1998) (dorso-lateral, intermediate and ventral-lateral segments).

This study seeks to highlight the segmentation of the LLD of the liver depending on the portal side intraparenchymal distribution of branches on the number of liver significant corrosion casts.

### Experimental part

In the present study, 160 human hepatic portal vein (HPV) system corrosion casts, achieved in the Department of Anatomy of the Victor Babes University of Medicine and Pharmacy Timisoara (prepared during 1994-2012), were analyzed. Liver pieces were harvested from human cadavers who had no history of abdominal surgical procedures or liver diseases. For obtaining the corrosion

casts, the liver vascular-ductal systems was injected between 1994 and 2005 with nitrocellulose paste (AGO II mass), and after 2005 with methacrylate copolymers (Technovit 7143). The corrosion of the liver parenchyma was performed with technic hydrochloric acid. All procedures for performing the liver corrosion casts were approved by the Ethics Committee of the Victor Babes University of Medicine and Pharmacy, Timisoara. The studied liver corrosion casts were classified according to the present type of major portal lateral branches (LBr) variation.

### Results and discussions

In all 160 pieces of hepatic corrosion casts, the left branch of the HPV has two parts: a transversal part and an umbilical part. We highlighted three morphological types of left branch origin: (i) from the PHV trunk by bifurcation of the PHV trunk in left and right branches (154 pieces 96.25% of cases), (II) from PHV trunk by trifurcation in left, anterior and posterior branches (4 pieces in 2.50% of cases); (iii) from anterior branch of the PHV, in situation in which the PHV trunk fork in anterior and posterior branches (2 pieces in 1.25% of cases). From the umbilical part arise the medial and LBr.

Regarding the intraparenchymal distribution of the portal LBr, we showed three distinct morphological types:

- Type I (143 casts, 89.375% of cases) in which from the umbilical part of the left branch arise two LBr with two subtypes:

- Subtype IA (55 pieces, 34.375% of cases) in which from the umbilical part of the left branch arise two efilates LBr: the superior LBr - branch of segments II and inferior LBr - branch of segment III (fig.1A);

- Subtype IB (88 pieces, 55.000% of cases) in which from the umbilical part of the left branch arise two LBr: the superior LBr with efilate aspect - branch of segments II, and inferior LBr forking *in buquet* - branch of segment III (fig.1B).

- Type II (17 casts, 10.25% of cases) in which from

\* email: tm10dis@yahoo.com ; Phone: 0745207408

the umbilical part of the left branch arise three LBr with two subtypes:

- Type IA (4 pieces, 2.500% of cases) in which from the umbilical part of the left branch arise three LBr: two superior LBr – for segments II and IIa, and one inferior LBr – for segment III (fig.1 C);

- Type IB (13 pieces, 8.125% of cases) in which from the umbilical part of the left branch arise three LBr: one superior LBr – for segments II, and two inferior LBr – for segments IIIa and III (fig.1 D).

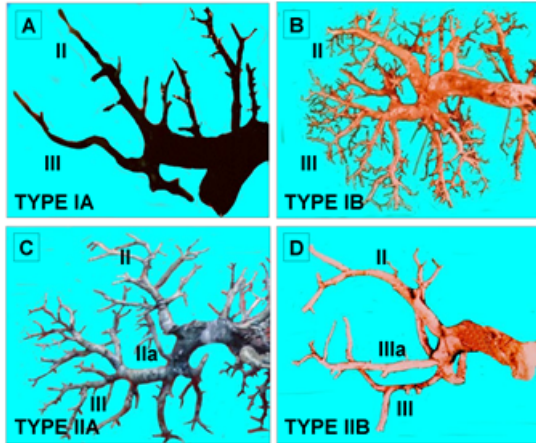


Fig.1. Corrosion cast of portal lateral branches; posterior view. The two distinct morphological types: A - type IA; B - type IB; C - type IIA; D - type IIB. II - segment II; IIa - segment IIa; III - segment III; IIIa - segment IIIa. [Color figure can be viewed in the online issue, which is available at [www.revmaterialeplastice.ro](http://www.revmaterialeplastice.ro)]

In Couinaud's classification [6], the LLD has a single segment, segment II. The segment III is included in the left medial division. Terminologia Anatomica [4] reconsidered the segmentation of the left part of the liver and included the segments II and III in the LLD. Right part of the liver parenchyma is more consistent as segmentation [7-9].

Only Platzer and Maurer [10] described the LLD with three segments, including the intermediary segment between segments II and III. The authors do not specify the affiliation of the intermediate branch to the superior or inferior LBr. On our cases, most of the intermediary branches belong to the group of inferior LBr (8.125% of the total of 10.625% cases with three LBr).

The presence of three LBr was correlated with the dorso-petal type of liver (in which the LLD has a larger volume (usually by the larger development of the segment III) [11, 12].

Comparison of the intraparenchymal distribution of the vascular-ductal hepatic elements reveals the symmetrical character of the LBr and medial branches of the arterial [13] and the bilio-ductal systems [13, 14], compared to the non-symmetrical character of the portal homologous branches [2, 9]. This aspect is determined by the pre- and post-natal evolution of the portal vascular system.

In a number of 500 cases, Lighezan et al., [9] (liver corrosion casts and MDCT angiography) also highlighted the quadrigintion of the liver portal vein trunk (0.2% of cases) and the asymmetric bifurcation of the right branch (13.2% of the cases).

For the training of students and residents in medicine, the anatomical study uses, apart from the classical dissection technique [15-17], the plastinated preparations

[18-20] and the corrosion casts [2, 8, 9, 14, 21]. In the case of parenchymal organs, the corrosion casts most closely outline the three-dimensional distribution of vascular-ductal elements.

## Conclusions

Study of intraparenchymatous distribution of the HPV branches can be achieved in good conditions on corrosion preparations. The most frequently (89.375% of the cases) - the LLD of the liver is served by two segmental branches (branch for segment II and branch for segment III); the intermediate LBr of the HPV is present in 10.625% of the cases. It belongs to the superior LBr in 2,500% of the cases and to the inferior LBr in 8,255% of cases. Knowledge of these morphological types of portal LBr is important for clinical and surgical practice.

## References

1. REX, H., *Morphol. Jahrb.*, 14, 1888, p. 517.
2. IOANOVICIU, S.D., IVAN, C., MATUSZ, P., OLARIU, S., LIGHEZAN, D., *Mat. Plast.*, **52**, no. 2, 2015, p. 113.
3. COUNAUD, C., *Le Foie. Etudes anatomiques et chirurgicales*. Masson et Cie Ed., Paris, 1957, pp.70-220.
4. FCAT. Federative Committee on Anatomical Terminology, *Terminologia Anatomica: international anatomical terminology*, 1st edn. Thieme, Stuttgart, 1998.
5. MATUSZ, P., RAICA, M., MATEESCU, R., ZAHOI, D., MEDERLE, C., *Elemente de morfo-fiziologie hepatica*. Editura Brumar, Timisoara, 2000.
6. COUNAUD, C., *Le Foie. Etudes anatomiques et chirurgicales*. Masson et Cie Ed., Paris, 1957, pp.70-220.
7. BISMUTH, H., HOUSIN, D., CASTAING, D., *World J. Surg.*, 6, 1982, p. 10.
8. IOANOVICIU, S.D., IVAN, C., MATUSZ, P., OLARIU, S., LIGHEZAN, D., *Mat. Plast.*, **52**, no. 2, 2015, p. 263.
9. LIGHEZAN, D.F., MATUSZ, P., IACOB, N., MICLAUS, G.D., PUSZTAI, A.M., HORDOVAN, E.C., BANCUI, C.D., BOIA, M., *Mat. Plast.*, **52**, no. 3, 2015, p. 357.
10. PLATZER, W., MAURER, H., *Acta Anat (Basel)*, 63, 1966, p. 8.
11. MATUSZ, P. *Tipologii de defasurare spatiale si interrelatii morfologice privind elementele de angio- si bilioarhitectura hepatica*, Teza de doctorat. UMF Timisoara; 1994.
12. PUSZTAI, A.M. *Corelatii intre tipologiile morfologice ale elementelor vasculare intraparenchimotoase ale partii stangi si forma exteriora a ficatului*. Teza de doctorat. UMF Victor Babes Timisoara, 2006.
13. MATUSZ, P. *Surg. Radiol. Anat.*, 33, no. 1, 2011, p. 71.
14. IVAN, C., NICA, C.C., DOBRESCU, A., BELIC, O., MATUSZ, P., OLARIU, S., *Mat. Plast.*, **52**, no. 1, 2015, p. 48.
15. WOOTEN, C., HAYAT, M., DU PLESSIS, M., CESMEBASI, A., KOESTERER, M., DALY, K.P., MATUSZ, P., TUBBS, R.S., LOUKAS, M., *Clin Anat.* 27, no. 8, 2014, p. 1264.
16. CESMEBASI, A., BAKER, A., DU PLESSIS, M., MATUSZ, P., TUBBS, R.S., LOUKAS, M., *Am. Surg.*, 81, no. 4, 2015, p. 365.
17. CESMEBASI, A., MUHLEMAN, M.A., HULSBURG, P., GIELECKI, J., MATUSZ, P., TUBBS, R.S., LOUKAS, M., *Clin. Anat.*, 28, no. 1, 2015, p. 101.
18. SORA, M.C., MATUSZ, P., *Clin Anat.* 25, nr. 2, 2012, p. 258.
19. SORA, M.C., JILAVU, R., MATUSZ, P., *Surg. Radiol. Anat.*, 34, nr. 8, 2012, p. 731.
20. SORA, M.C., MATUSZ, P., *Clin. Anat.*, 23, nr. 6, 2010, p. 734.
21. BEDREAG, O., BUT, A.R., HOINOIU, B., MICLAUS, G.D., URSONIU, S., MATUSZ, P., DOROS, C.I., *Mat. Plast.*, **51**, no. 4, 2014, p. 444.

Manuscript received: 16.03.2017